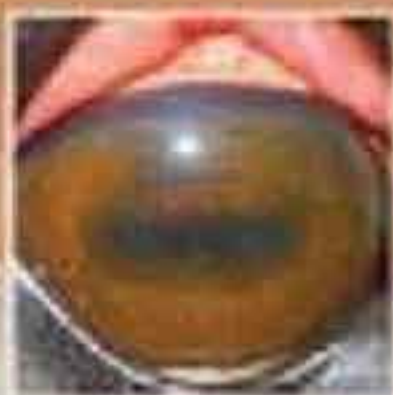
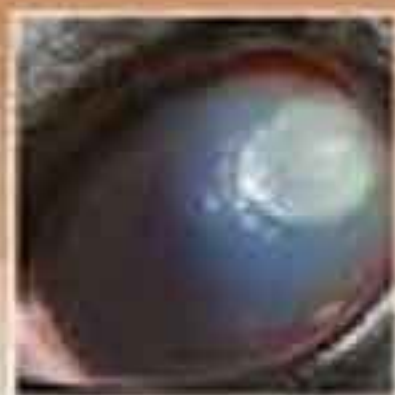


Third Edition

EQUINE

Ophthalmology

Edited by
Brian C. Gilger



WILEY Blackwell

Equine Ophthalmology

Third Edition

Edited by

Brian C. Gilger

North Carolina State University

WILEY Blackwell

This edition first published 2017 © 2017 by John Wiley & Sons, Inc.
Second edition 2011 © 2011 by Saunders, an imprint of Elsevier Inc.
First edition 2005 © 2005 by Saunders, an imprint of Elsevier Inc.

Editorial Offices

1606 Golden Aspen Drive, Suites 103 and 104, Ames, Iowa 50010, USA
The Atrium, Southern Gate, Chichester, West Sussex, PO19 8SQ, UK
9600 Garsington Road, Oxford, OX4 2DQ, UK

For details of our global editorial offices, for customer services and for information about how to apply for permission to reuse the copyright material in this book please see our website at www.wiley.com/wiley-blackwell.

Authorization to photocopy items for internal or personal use, or the internal or personal use of specific clients, is granted by Blackwell Publishing, provided that the base fee is paid directly to the Copyright Clearance Center, 222 Rosewood Drive, Danvers, MA 01923. For those organizations that have been granted a photocopy license by CCC, a separate system of payments has been arranged. The fee codes for users of the Transactional Reporting Service are ISBN-13: 978-1-119-0477-4/2017.

Designations used by companies to distinguish their products are often claimed as trademarks. All brand names and product names used in this book are trade names, service marks, trademarks or registered trademarks of their respective owners. The publisher is not associated with any product or vendor mentioned in this book.

The contents of this work are intended to further general scientific research, understanding, and discussion only and are not intended and should not be relied upon as recommending or promoting a specific method, diagnosis, or treatment by health science practitioners for any particular patient. The publisher and the author make no representations or warranties with respect to the accuracy or completeness of the contents of this work and specifically disclaim all warranties, including without limitation any implied warranties of fitness for a particular purpose. In view of ongoing research, equipment modifications, changes in governmental regulations, and the constant flow of information relating to the use of medicines, equipment, and devices, the reader is urged to review and evaluate the information provided in the package insert or instructions for each medicine, equipment, or device for, among other things, any changes in the instructions or indication of usage and for added warnings and precautions. Readers should consult with a specialist where appropriate. The fact that an organization or Website is referred to in this work as a citation and/or a potential source of further information does not mean that the author or the publisher endorses the information the organization or Website may provide or recommendations it may make. Further, readers should be aware that Internet Websites listed in this work may have changed or disappeared between when this work was written and when it is read. No warranty may be created or extended by any promotional statements for this work. Neither the publisher nor the author shall be liable for any damages arising herefrom.

Library of Congress Cataloging-in-Publication Data

Names: Gilger, Brian C., editor. | Preceded by (work): Gilger, Brian C. Equine ophthalmology.
Title: Equine ophthalmology / edited by Brian C. Gilger.
Other titles: Equine ophthalmology (Gilger)
Description: Third edition. | Ames, Iowa : John Wiley & Sons Inc., 2017. |
Preceded by: Equine ophthalmology / Brian C. Gilger. 2nd ed. c2011. |
Includes bibliographical references and index.
Identifiers: LCCN 2016026245 | ISBN 9781119047742 (cloth) | ISBN 9781119047858 (Adobe PDF) |
ISBN 9781119047995 (ePub)
Subjects: LCSH: Equine ophthalmology. | MESH: Horse Diseases | Eye Diseases--veterinary
Classification: LCC SF959.E93 G55 2017 | NLM SF 959.E93 | DDC 636.1/08977--dc23
LC record available at <https://lcn.loc.gov/2016026245>

A catalogue record for this book is available from the British Library.

Wiley also publishes its books in a variety of electronic formats. Some content that appears in print may not be available in electronic books.

Cover image: BOB BALMER IMAGES/Gettyimages

Set in 9.5/12pt Minion by SPI Global, Pondicherry, India

Contents

- List of contributors, iv
- Preface to the third edition, vi
- About the companion website, vii
- 1** Equine ocular examination basic techniques, 1
Riccardo Stoppini and Brian C. Gilger
- 2** Advanced ophthalmic imaging in the horse, 40
Eric C. Ledbetter and Ruth A. Van Hatten
- 3** Practical field ophthalmology, 72
Ann E. Dwyer
- 4** Ophthalmic diseases of foals, 112
Marta Leiva and Teresa Peña
- 5** Diseases and surgery of the globe and orbit, 151
Claudia Hartley and Rachael A. Grundon
- 6** Diseases of the adnexa and nasolacrimal system, 197
Elizabeth A. Giuliano
- 7** Diseases of the cornea, 252
Dennis E. Brooks, Andrew Matthews, and Alison B. Clode
- 8** Diseases of the uvea, uveitis, and recurrent uveitis, 369
Brian C. Gilger and Steven R. Hollingsworth
- 9** Diseases and surgery of the lens, 416
Richard J. McMullen Jr and Brian C. Gilger
- 10** Glaucoma, 453
David A. Wilkie, Anne J. Gemensky-Metzler, Mary Lassaline, and Dennis E. Brooks
- 11** Diseases of the equine vitreous and retina, 469
Rachel A. Allbaugh, Wendy M. Townsend, and David A. Wilkie
- 12** Equine vision, 508
Paul E. Miller and Christopher J. Murphy
- 13** Inherited ocular disorders, 545
Lynne Sheila Sandmeyer and Rebecca Bellone
- 14** Equine neuro-ophthalmology, 567
Elsa Beltran, Kaspar Matiasek, and Claudia Hartley
- 15** Ocular manifestations of systemic disease, 591
Jennifer L. Davis
- 16** National and international regulations on ophthalmic disease and medications, 624
Mary Lassaline
- 17** Management of blind horses, 629
Ann E. Dwyer
- Index, 649

List of contributors

Rachel A. Allbaugh

Diplomate ACVO
Assistant Professor
Department of Veterinary Clinical Sciences
Iowa State University
Ames, Iowa, USA

Rebecca Bellone

Associate Adjunct Professor
Department of Population Health and Reproduction
Veterinary Genetics Laboratory
School of Veterinary Medicine
University of California-Davis
Davis, California, USA

Elsa Beltran

European and Royal College Recognised Specialist in Veterinary Neurology
Lecturer in Veterinary Neurology and Neurosurgery
Department of Clinical Science and Services
The Royal Veterinary College
University of London
Hatfield, UK

Dennis E. Brooks

Professor of Ophthalmology
College of Veterinary Medicine
University of Florida
Department of Small Animal Clinical Sciences
Gainesville, Florida, USA

Alison B. Clode

Ophthalmologist
Port City Veterinary Referral Hospital
Portsmouth, New Hampshire, USA

Jennifer L. Davis

Associate Professor of Equine Internal Medicine
North Carolina State University College of Veterinary Medicine
Raleigh, North Carolina, USA

Ann E. Dwyer

Practitioner
Genesee Valley Equine Clinic PLLC
Scottsville, New York, USA

Anne J. Gemensky-Metzler

Diplomate ACVO
Professor
Department of Veterinary Clinical Sciences
The Ohio State University College of Veterinary Medicine
Columbus, Ohio, USA

Brian C. Gilger

Professor of Ophthalmology
North Carolina State University College of Veterinary Medicine
Raleigh, North Carolina, USA

Rachael A. Grundon

Clinician in Comparative Ophthalmology
Fellow ANZCVS(Ophthal)
Animal Health Trust
Newmarket, UK

Elizabeth A. Giuliano

Diplomate, ACVO
Professor of Comparative Ophthalmology
College of Veterinary Medicine
University of Missouri
Columbia, Missouri, USA

Claudia Hartley

European and Royal College Recognised Specialist in Veterinary Ophthalmology
Animal Health Trust
Newmarket, UK

Steven R. Hollingsworth

Professor of Clinical, Surgical & Radiological Sciences
University of California
Surgical and Radiological Science
Davis, California, USA

Mary Lassaline

Associate Professor of Clinical Equine Ophthalmology
Department of Surgical and Radiological Sciences
School of Veterinary Medicine
University of California, Davis
Davis, California, USA

Eric C. Ledbetter

Associate Professor of Ophthalmology
Department of Clinical Sciences
Cornell University
College of Veterinary Medicine
Hospital for Animals
Ithaca, New York, USA

Marta Leiva

Diplomate ECVO
Assistant Professor of Ophthalmology
Department of Animal Medicine and Surgery
Autonomous University of Barcelona
Barcelona, Spain

Kaspar Matiasek

Professor and Section Head of Clinical and Comparative Neuropathology
Centre for Clinical Veterinary Medicine
Ludwig-Maximilians-University
Munich, Germany

Andrew Matthews

Bents Cottage
Red Castle, Lunan Bay
Inverkeilor, Angus, Scotland, UK

Richard J. McMullen Jr

Diplomate ACVO, ECVO
Associate Professor
Department of Clinical Sciences
Auburn University
Auburn, Alabama, USA

Paul E. Miller

University of Wisconsin–Madison
Department of Surgical Sciences
Madison, Wisconsin, USA

Christopher J. Murphy

University of California
Surgical and Radiological Science
Davis, California, USA

Teresa Peña

Diplomate ECVO
Associate Professor of Ophthalmology
Department of Animal Medicine and Surgery
Autonomous University of Barcelona
Barcelona, Spain

Lynne Sheila Sandmeyer

Diplomate American College of Veterinary Ophthalmology
Professor of Veterinary Ophthalmology
Department of Small Animal Clinical Sciences
Western College of Veterinary Medicine
University of Saskatchewan
Saskatoon, Saskatchewan, Canada

Riccardo Stoppini

Consultant in Equine Ophthalmology
Calvagese della Riviera, Italy

Wendy M. Townsend

Diplomate ACVO
Associate Professor
Department of Veterinary Clinical Sciences
Purdue University
West Lafayette, Indiana, USA

Ruth A. Van Hatten

Staff Radiologist
Angell Animal Medical Center
Boston, Massachusetts, USA

David A. Wilkie

Diplomate ACVO
Professor
Department of Veterinary Clinical Sciences
The Ohio State University
Columbus, Ohio, USA

Preface to the third edition

It has been over a decade since the first edition of *Equine Ophthalmology* was published. The field of equine ophthalmology has grown through the efforts of pioneers, such as Drs Dennis Brooks, Andy Matthews, Dan Lavach, and Bill Rebhun, to name a few. Also, the International Equine Ophthalmology Consortium (IEOC), an organization created in 2009, has pushed the advancement of equine ophthalmology through sharing of information and development of collaborations among interested practitioners and researchers throughout the world. My hope is that this organization continues to grow and spurs the further study of equine ophthalmology.

A goal of *Equine Ophthalmology* has always been to provide a comprehensive source of information to assist veterinarians in the diagnosis and treatment of ophthalmic diseases in horses. To assist this effort, the authors of individual chapters have included numerous images, figures, and detailed treatment plans. However, it is the responsibility of each practitioner to verify dosages and treatments for each individual horse. Also, most figures in this new edition have been redrawn from the second edition to improve clarity and accuracy.

Another goal of this book is to provide a comprehensive source of information and references to assist with research and publications in equine ophthalmology. I believe the previous editions of equine ophthalmology have been extremely helpful as a source of information and the basis of clinical studies, and I am sure that this new edition will be even better.

A final goal of *Equine Ophthalmology* is simply to provide education for all of us—from students to specialists. I have learned a tremendous amount from the incredible knowledge and experience of the authors of this new edition.

There are numerous changes in this third edition of *Equine Ophthalmology*. With the expanded content and information available on equine ocular disorders, we have provided online supplementary materials, including expanded content and figures to augment the print and digital versions of the textbook. Please see links in the text to view the expanded online content. We have new authors in many chapters, including the orbit, cornea, glaucoma, posterior segment, and inherited disease. I thank the authors of these chapters in previous editions who have provided the basis for these important chapters. In addition, there are new chapters for this third edition, including advanced diagnostics, foal ophthalmology, neuro-ophthalmology, and national and international regulations, and an expanded chapter on inherited ocular disease. These new chapters reflect the growing knowledge and importance of these subject areas in equine ophthalmology.

This is an excellent comprehensive textbook on equine ophthalmology, which I am very proud of—I hope you enjoy it as much as we have putting it together and I hope it is a constant resource to assist you in the management of your equine cases.

Brian C. Gilger
Raleigh North Carolina, USA

About the companion website


This book is accompanied by a companion website:

www.wiley.com/go/gilger/ophthalmology

The website includes additional text, figures, and tables that are not in the printed book or E-book.

How to access the website:

1. Carefully scratch away the top coating on the label, below, to reveal the PIN code.
2. Go to www.wiley.com/go/gilger/ophthalmology to register your PIN and access the site.



CHAPTER 1

Equine ocular examination basic techniques

Riccardo Stoppini and Brian C. Gilger*

Introduction

The basic and essential aspect of equine ophthalmology is a complete, thorough ocular examination. In this chapter, ophthalmic examination of the horse is discussed, with emphasis on techniques, tools, and instruments, and basic diagnostic modalities. Understanding normal equine ocular anatomy is integral to interpreting the ocular examination. Anatomy of every equine ocular compartment (Figure 1.1) is described in detail in subsequent chapters and is not discussed here, although cross-references to relevant sections in the book will augment our discussion. Excellent reviews of equine eye and head anatomy can also be found in other sources [1–6].

Routine ophthalmic diagnostic techniques are described here, while advanced diagnostic techniques are discussed in Chapter 2. Examination of the equine eye includes obtaining a detailed history and signalment, inspecting the patient in a well-lit environment, examining the ocular structures in a darkened environment, facilitating the examination with restraint, sedation, and local nerve blocks, and collecting relevant diagnostic samples or data [4, 7–10].

Medical history

A thorough medical history relevant to the ocular examination should include how the animal is used (e.g., pet or performance) and its living environment. Additional information that should be collected includes any history of travel, vaccination history, deworming schedule, and presence of concurrent or previous medical problems such as nasal discharge, presence of stridor,

previous trauma to the head, and status of other horses on the premises with similar signs (Box 1.1). Characterization of the primary complaint should include the onset and initial clinical signs, treatment given and response to that treatment, progression and duration of the ocular problem, and current therapy. Signalment can provide an important clue as to the cause of many ophthalmic conditions (e.g., congenital stationary night blindness in the Appaloosa, hereditary cataracts in the Morgan horse). Existing medical therapy can also greatly influence findings on ophthalmic examination. For example, a finding of mydriasis on the ophthalmic examination could be caused by use of topical atropine, which may result in mydriasis for up to 14 days in horses [11]. Depending on the specific complaint, further information may be required, such as a thorough description of vision loss (e.g., light versus dark, moving objections, one eye or both) or changes in behavior during sport activity.

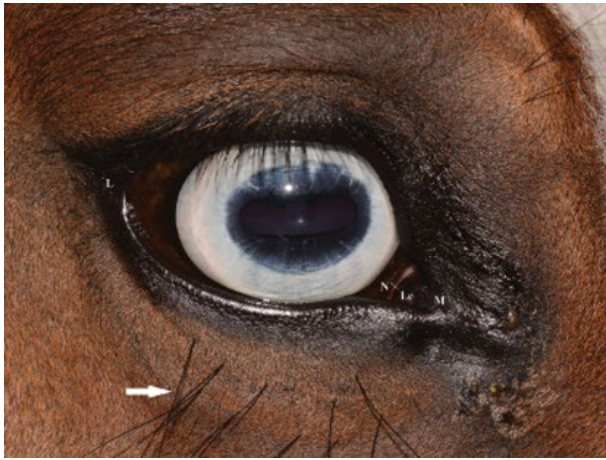Routine and advanced equipment required for the ophthalmic examination

Prior to any examination, the proper equipment to perform the examination is needed. Although there are some differences in opinion and personal preferences among equine ophthalmologists, Box 1.2 lists the routine and advanced equipment a clinician should have available for the ophthalmic examination. Routine materials for the examination are shown in Figures 1.2 and 1.3.

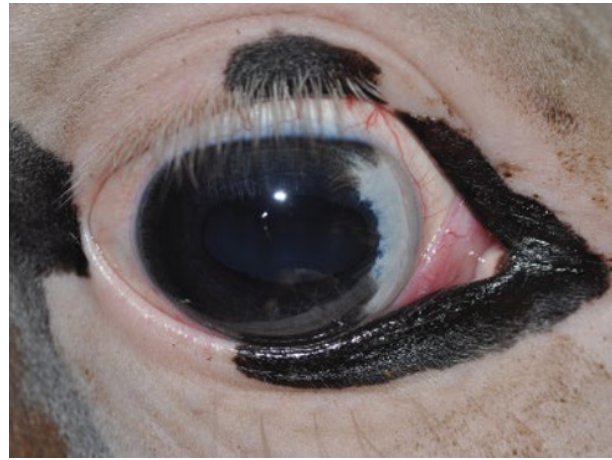Overview and methods of the equine ocular examination

Ocular examination in the horse, like any physical examination, should be performed in a systematic manner, and to help remember the steps, the compilation of a clinical report or

* The authors would like to thank Dr Tammy Miller Michau for her contributions. She was the author of this chapter in the first edition of *Equine Ophthalmology*.



(A)



(B)

Figure 1.1 (A) Normal external appearance of the equine eye. The horse's palpebral fissure, cornea, and pupil are oval horizontally. The lateral canthus (L) is more rounded than the medial canthus (M). There are prominent folds in the upper and lower eyelids. Numerous eyelashes are present along the lateral two-thirds of the upper eyelid, and vibrissae are located dorsonasal to the upper lid and ventral to the lower lid (arrow). The leading edge of the third eyelid is usually partially pigmented (N). The lacrimal caruncle (Lc) is prominent. (B) Normal external appearance of the equine eye when eyelid pigment is absent. Note the lack of pigment on the third eyelid, conjunctiva, and sclera as well.

Box 1.1 Anamnesis and horse history.

- Horse attitude and use (jumping, trotter, dressage, pleasure, etc.)
- Travel and environment history
- Medical history (previous trauma, incident, etc.)
- Time of purchase and PPE (pre-purchase examination)
- Horses in contact and eventual infectious diseases
- Vaccination status
- Deworming history
- Reaction/drug anaphylaxis events
- Breeding info (in case possible presence of heritable pathologies)
- Previous medical history (PMH) (nasal discharge, coughing, colic, etc.)
- Previous ocular history
- Previous ocular treatments (medical/surgical)
- Previous abnormal/changed behavior

examination sheet may be helpful (Box 1.3). The general order of steps to be taken is shown in Box 1.4. The initial examination of the equine eye should occur prior to sedation and should take place in a well-lit area. The examination area should be quiet, away from distractions, and if possible away from other horses. The menace response and other subjective vision testing (e.g., maze testing) and evaluation of the pupillary light reflex (PLR) should be performed before sedation. For accurate evaluation of PLRs, a bright focal light source and a darkened examination area are often required. To adequately examine the cornea and internal structures of the eye, the horse must be examined in a darkened stall or in stocks in a room where the lights can be dimmed. Ideally, stocks are preferred because they will better protect the examiner from accidental (or purposeful!) movements of the horse, which can be exaggerated and unpredictable when the horse is tranquilized.

A thorough ocular examination usually requires appropriate restraint, tranquilization, regional nerve blocks, and topical anesthesia. Methods of restraint required to examine the ocular

Box 1.2 Equipment and supplies for general equine ophthalmic examination.

Routine equipment and supplies

- Bright focal light source: Finnoff halogen transilluminator
- Direct ophthalmoscope, PanOptic ophthalmoscope, or indirect ophthalmoscope with 20-D lens
- Sterile dye strips (fluorescein, rose bengal, lissamine green)
- STT
- Sterile culture swabs for cytology and culture
- Kimura platinum spatula, #10 to #15 sterile surgical blade (cytology)
- Glass slides (cytology)
- Sterile eyewash
- Ophthalmic lubricant, artificial tears ointment
- Topical anesthetic: proparacaine HCl 0.5%
- Short-acting dilating agent: tropicamide HCl 1%
- Sedatives: detomidine HCl, xylazine, acepromazine, romifidine, etc.
- Local nerve block agents: mepivacaine HCl, lidocaine HCl, bupivacaine HCl
- Graefe fixation forceps (to manipulate conjunctiva and third eyelid)
- Digital tonometer (Tono-Pen or TonoVet tonometer)
- Open-ended tomcat urinary catheter for nasolacrimal irrigation
- 1- and 3-mL syringes, 18- and 25-G needles
- 12-mL syringes for nasolacrimal irrigation

Advanced equipment and supplies

- All supplies and instruments for routine examination
- Handheld slit-lamp biomicroscope
- Binocular indirect ophthalmoscope and lenses (15-, 20-, 30-D or 2.2 panretinal)
- Ultrasound (7.5-, 10-, and 20-MHz probe)
- Sterile methylcellulose gel for ultrasound
- Electroretinogram
- 19-G, 3½-inch spinal needle for retrobulbar block
- 27-G needle for aqueocentesis
- Digital camera (color and infrared)
- Advanced imaging: radiography, computed tomography (CT), magnetic resonance imaging (MRI)

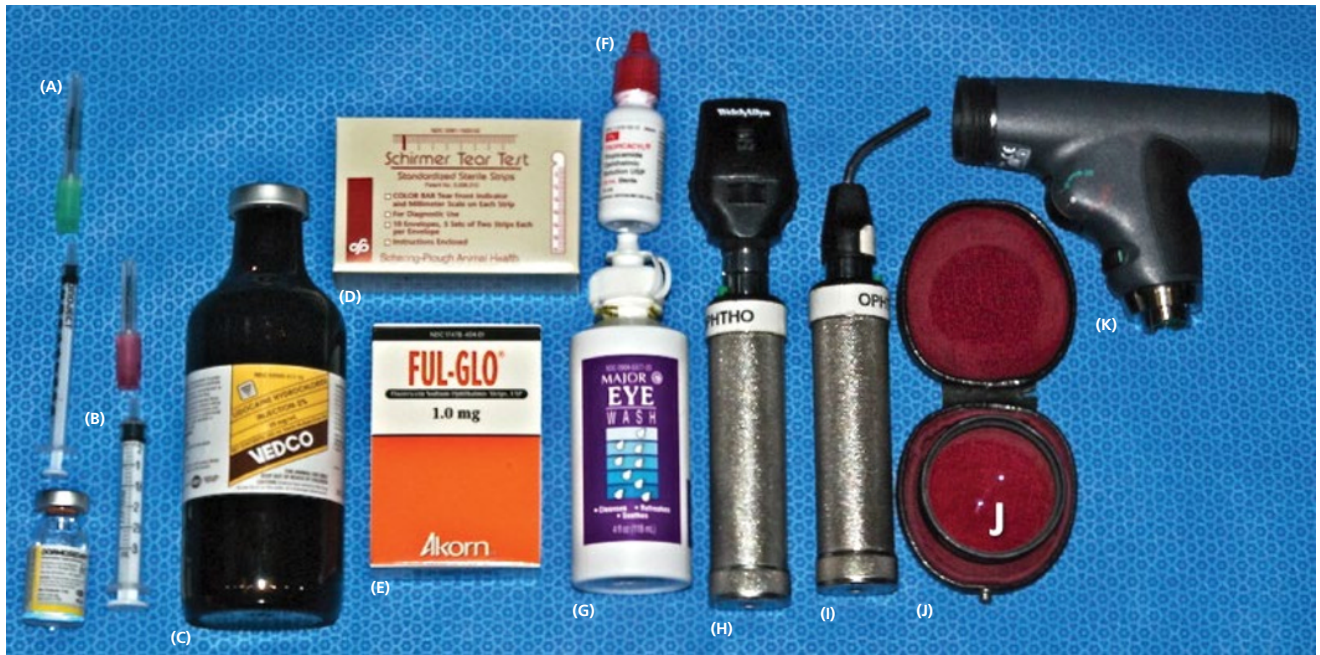

Figure 1.2 Materials and supplies for a routine ophthalmic examination in the horse. (A) 18-G, 1½-inch needle, 25-G, 1-inch needle, 1 mL and 3 mL syringes. (B) Tranquilizer (detomidine). (C) 2% Lidocaine HCl. (D) STT strips. (E) Fluorescein dye strips. (F) 1% Tropicamide HCl. (G) Sterile eyewash. (H) Direct ophthalmoscope. (I) Finnof transilluminator. (J) Indirect ophthalmoscopy lens (20 D). (K) Panoptic ophthalmoscope.

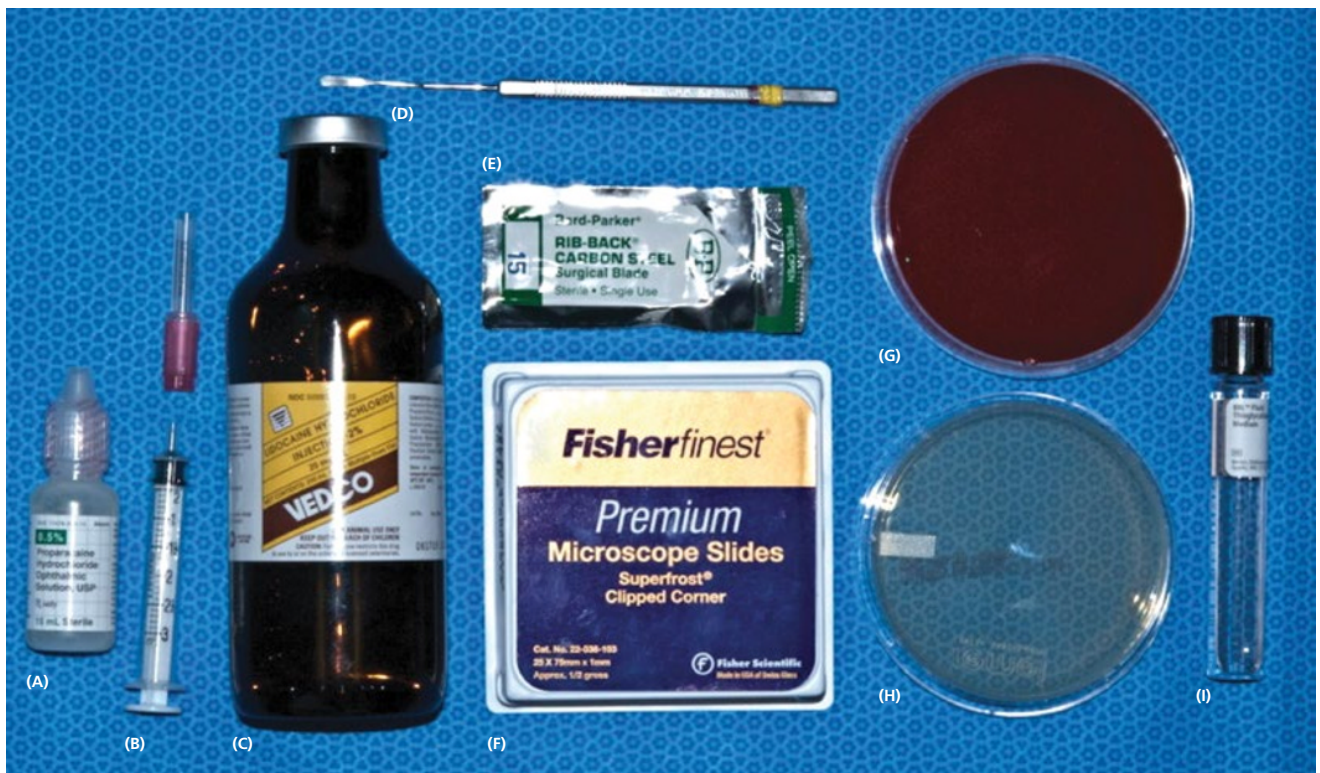

Figure 1.3 Materials for collection of corneal culture and cytology. (A) 0.5% Proparacaine HCl. (B) 25-G, 1-inch needle and 3-mL syringe. (C) 2% Lidocaine HCl. (D) Kimura platinum spatula. (E) #15 surgical blade. (F) Microscope slides. (G) Blood agar culture plate. (H) Sabouraud agar culture plate. (I) Thyoglycolate medium.

Box 1.3 Equine ophthalmology examination form.

Equine Ophthalmology Examination Form

Owner: _____

Referring Veterinarian: _____

Horse: _____

First visit: _____

Remote history: _____

Recent history: _____

RIGHT EYE

PLR dir: _____

PLR cons: _____

Dazzle Refl: _____

Corneal Rfl: _____

Palpebral Rfl: _____

Menace response: _____

IOP: _____

SIT I-II: _____

TBUT: _____

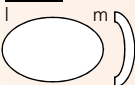
Globe and orbit: _____

Eyelids _____


Conjunctiva: _____

NLD: _____

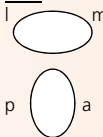
Cornea: _____



Iris and AC: _____




Lens: _____



Vitreous: _____

Fundus: _____



LEFT EYE

PLR dir: _____

PLR cons: _____

Dazzle Refl: _____

Corneal Rfl: _____

Palpebral Rfl: _____

Menace response: _____

IOP: _____

SIT I-II: _____

TBUT: _____

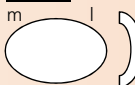
Globe and orbit: _____

Eyelids _____


Conjunctiva: _____

NLD: _____

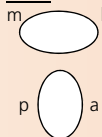
Cornea: _____



Iris and AC: _____




Lens: _____



Vitreous: _____

Fundus: _____



structures of the horse range from a halter and lead rope to mechanical restraint in stocks with use of a lip twitch. Use of restraint is dependent on temperament of the horse and experience of the handlers and examiner. Use of a tranquilizer is generally recommended, and frequently needed, to facilitate the complete routine ophthalmic examination.

Initial examination

With the examiner positioned in front of the horse, the head, bony orbits, eyelids, globes, and pupils should be examined for symmetry (Figure 1.4) before touching the eyelids, giving sedation, or use of eyelid nerve blocks. Ocular comfort may be assessed by evaluation of palpebral fissure size and symmetry,

Box 1.4 General order of steps in the routine equine ocular examination.

- 1 Obtain medical and ocular history.
- 2 Examine horse in its environment.
 - Observe walking on a lead or loose in a stall or round pen.
 - Observe horse performing activity such as jumping, cutting, etc.
- 3 Evaluate for symmetry from the front of the head.
 - Observe globe, orbit, pupils, eyelash direction, ear and lip position.
- 4 Perform vision testing.
 - Menace response, dazzle reflex, maze testing.
- 5 Perform palpebral and pupillary light reflexes.
- 6 Perform STT if indicated.
- 7 Administer sedation if required.
- 8 Perform palpebral nerve block.
- 9 Use direct transillumination for gross disease of eyelids, cornea, anterior chamber, and iris.
- 10 Collect samples for culture and cytology if indicated.
- 11 Perform detailed examination of the eyelids, cornea, anterior chamber, and iris with transillumination and biomicroscopy.
- 12 Test corneal reflex.
- 13 Apply topical fluorescein and examine the cornea.
- 14 Apply topical anesthesia if indicated.
- 15 Perform tonometry.
- 16 Induce mydriasis (tropicamide HCl) if not contraindicated.
- 17 Perform detailed examination of the lens and vitreous, via transillumination, retroillumination, and biomicroscopy.
- 18 Perform direct and/or indirect ophthalmoscopy.
- 19 Irrigate nasolacrimal duct(s) if indicated.

position of the eyelashes, ocular discharge, and blink rate [4, 8, 9]. The upper eyelashes of the healthy horse are nearly perpendicular to the cornea (Figure 1.5A) [8]. A ventral or downward direction of the eyelashes in relation to the cornea may indicate blepharospasm, enophthalmos, or ptosis (see Figure 1.4B–D and Figure 1.5B), while an upward deviation may indicate exophthalmos or an enlarged eye (see Figure 1.4C) [8].

The examiner should then be positioned at the side of the horse's head to examine each eye individually. An assistant may be required to elevate the head of a sedated horse to the same level as the examiner's eyes. The examiner may need to use a stool for an extremely tall horse or kneel on the ground for an extremely short horse (e.g., Miniature horse), although this should be done with great caution and never directly in front of the horse.

A cranial nerve (CN) evaluation (specifically, CN II, III, IV, V, VI, VII) is then performed before any sedation is induced. These CNs are assessed via the menace response, pupillary light and dazzle reflexes, globe and eyelid position and mobility, and sensation of ocular and adnexal structures [8, 9]. Examination of the CNs is discussed in more detail in the following section.

The cornea should be examined for abnormalities (e.g., opacities, ulceration, blood vessels, edema) by using transillumination and/or slit-lamp biomicroscopy. Evaluation of resting pupil size, shape, and mobility, and appearance of the anterior chamber structures should follow, including the assessment for aqueous flare. The attachment of the iridocorneal angle

pectinate ligaments to Descemet's membrane (i.e., gray line) can be observed medially and laterally in the adult horse (Figure 1.6A, B) and allows for direct visualization of the horse's iridocorneal angle. Collection of cultures and Schirmer tear values are performed, when indicated, prior to placing any medications into the eyes. When indicated, cytology is collected next, usually after application of topical anesthetic (e.g., proparacaine HCl 0.5%, oxibuprocaine chloridrate 0.4%, tetracaine). Fluorescein staining of the cornea is then performed. Examination of the nasolacrimal system, third eyelid, and conjunctiva is performed concurrently. Fluorescein staining is followed by induction of topical anesthesia, if not already given to collect cytology and perform tonometry. The ocular media (cornea, aqueous humor, lens, and vitreous) are evaluated for clarity and transparency by transillumination and ophthalmoscopy [4, 9]. The anterior surface of the third eyelid can be examined by gently retropulsing the globe to produce passive prolapse of the nictitans. For evaluation of the posterior surface, the third eyelid can be gently grasped with Graefe fixation forceps or manipulated with a strabismus hook.

For complete examination of the lens and posterior segment, mydriasis is required. The most common mydriatic used is 1% tropicamide HCl eyedrops, which takes effect in approximately 10–20 minutes and lasts 4–6 hours [12, 13]. In the case of severe intraocular inflammation or reflex uveitis because of corneal disease or trauma, a single application of tropicamide may not be sufficient to dilate the pupil. Topical phenylephrine (2.5% or 10%) does not cause mydriasis in normal horses, nor does it enhance the mydriatic effect of tropicamide [14, 15]. The use of atropine for routine examination is not recommended because of its longer duration of action and potential adverse effects in the horse [11, 16]. After mydriasis has been achieved, the clarity, position, and size of the lens, vitreous body, optic nerve, retinal blood vessels, and the tapetal and nontapetal fundus are evaluated. With full mydriasis, the edge of the lens and attachment of the zonular fibers may be visible [17].

Cranial nerve examination

For a breakdown of the CN examination see Table 1.1.

Vision testing

Vision testing in horses is subjective. Environmental observation, menace response, dazzle reflex, and maze testing provide only rough data. Determining total blindness is possible with these tests, but determining whether a horse has decreased vision is not easily done. Advanced diagnostic testing, such as electroretinography (see section **Electroretinography**), may help to determine if there are abnormalities in retinal electrical function but do not test vision per se. If visual function is in doubt in one or both eyes, the horse can have a unilateral blindfold and be subjected to a maze test. However, horses that are depressed, are ataxic, or have vestibular disease may stumble over objects despite having vision [9]. Equine vision and vision testing are discussed more extensively in Chapter 12.

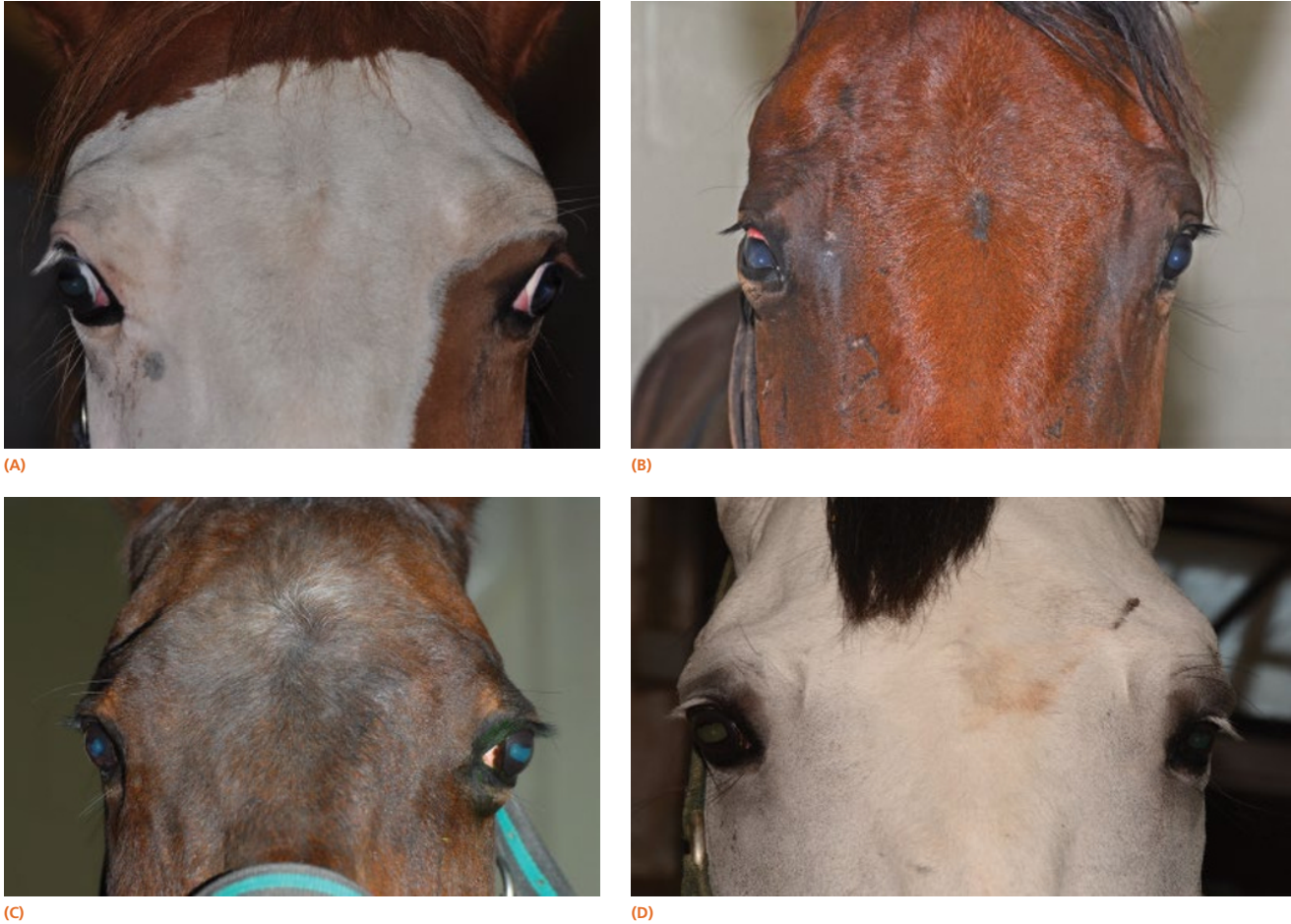

Figure 1.4 (A) The head (including ears and nostrils), bony orbits, eyelids, globes, and pupils should be examined for symmetry, with the examiner positioned in front of the horse. (B) Horse with orbital asymmetry due to an orbital fracture on the right side. (C) Horse with asymmetry due to a retrobulbar mass resulting in exophthalmos on the left side. (D) Horse with orbital asymmetry due to an orbital fracture resulting in enophthalmos on the left side.




Figure 1.5 (A) The cornea and eyelids as viewed from the front in a healthy horse. The upper eyelashes are nearly perpendicular to the cornea. (B) The cornea and eyelids as viewed from the front in a horse with ocular pain. The eyelashes are no longer at 90 degrees from the corneal surface but are pointed downward.

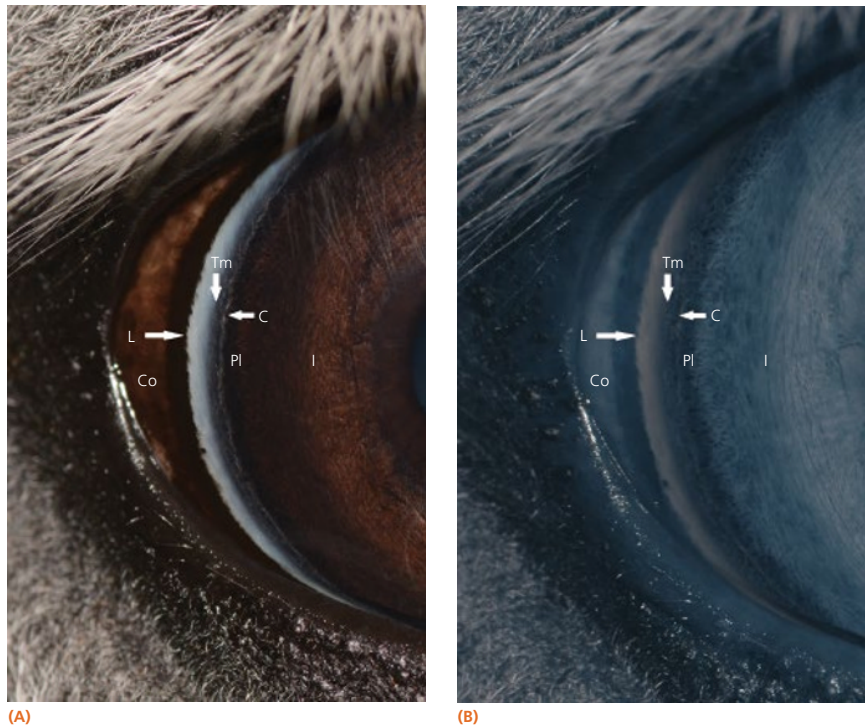

Figure 1.6 (A) The attachment of the iridocorneal angle pectinate ligament to Descemet's membrane (i.e., gray line) can be observed medially and laterally in the adult horse. Iris (I), pectinate ligaments (Pl), attachment of pectinate ligaments to corneal endothelium (C), trabecular meshwork (Tm), limbus (L), and conjunctiva (Co). (B) More details are visible at infrared picture.

Table 1.1 Cranial nerve examination.

CN	Name	Motor (M) or sensory (S)	Function	Dysfunction	Assessment
II	Optic	S	Vision Pupillary light pathway	Blindness	Menace response Pupillary light reflex Dazzle reflex
III	Oculomotor	Medial, dorsal, ventral rectus (M), ventral oblique Pupillary sphincter muscle (M) Levator palpebrae superioris (M)	Globe movement Pupillary function Upper eyelid elevation	Lateral strabismus Mydriasis Ptosis	Eye position Pupillary light reflexes
IV	Trochlear	Superior oblique (M)	Globe movement	Dorsomedial strabismus	Move head and observe eye position
V	Trigeminal	Maxillary branches: skin of face/eyelid (S) Ophthalmic branches: eye (S)	Sensation of skin, eyelids, and cornea	Neurotrophic keratitis	Corneal reflex
VI	Abducens	Lateral rectus (M), retractor bulbi	Globe movement	Medial strabismus	Move head and observe eye position
VII	Facial	Orbicularis oculi (M) Lacrimal gland (M)	Close palpebral fissure Stimulates tear production	Exposure keratitis KCS	Observation Palpebral reflex STT
VIII	Vestibulocochlear		Equilibrium	Spontaneous nystagmus	Observation

Menace response

The menace response is a learned protective response in which a menacing movement toward the eye results in closure of the eyelids and possibly retraction of the globe or an avoidance movement of the head [12]. The threatening movement can be performed with the examiner's hand, but care should be taken to avoid contacting the vibrissae and to avoid causing an air current that could be detected even in a blind eye. For detection

of a visual deficit in one field, the menacing gesture is directed first toward the nasal visual fields and then toward the temporal visual fields [18]. However, partial visual deficits can be extremely difficult to detect using a menace response. The afferent arm of the menace response is the retina and CN II, and the efferent arm is the palpebral branch of CN VII, which innervates the orbicularis oculi muscle (see Chapter 14) [19]. A horse that has intact vision but is extremely stoic, depressed,

or frightened may have a diminished menace response. Lightly tapping the medial or lateral canthus before attempting to induce the menace response again may heighten the response from an uninterested, stoic horse. A pathologic lack of menace response may result from a lesion in the retina, CN II, visual cortex, or CN VII [19]. Cerebellar disease can also cause bilateral deficiency in the menace response in the absence of blindness or CN VII paralysis, possibly because of a loss of cerebellar modulation of cerebral visual function [18, 19].

Pupillary light reflexes

Both eyes should be examined for pupil size and symmetry and for abnormalities such as synechia that may affect the PLR. One method to observe pupil symmetry in the horse is to use an indirect or direct ophthalmoscope directed at the center of the horse's head from a distance of 1.5–2.0 m. This technique will illuminate the pupils via both tapetal reflexes and make it possible to evaluate pupil symmetry (Figures 1.7 and 1.8) [20]. Anisocoria may be a normal finding in horses with bilateral heterochromia iridis or unilateral heterochromia iridis in which the larger pupil is ipsilateral to the heterochromic eye (Figure 1.9) [6].

When stimulated by light during the PLR, vertical movement of the pupil is much faster and excursion is greater than horizontal movement. The pupil's shape is a horizontal ellipse that becomes rounder when dilated (Figures 1.10 and 1.11) [21]. Pupillary light reflexes can be used to simultaneously evaluate function of the retina, CN II, midbrain, and CN III [18–20]. Light directed into one eye should result in constriction of both that pupil (direct response) and the pupil of the contralateral eye (indirect or consensual response). This results from bilateral excitation of the parasympathetic component of CN III in the pretectal region [18–20]. The normal equine pupil responds




Figure 1.7 With the examiner 1.5–2.0 m in front of the horse, an indirect ophthalmoscope directed at the center of the horse's head should illuminate both tapetal reflexes and make it possible to determine pupil symmetry.

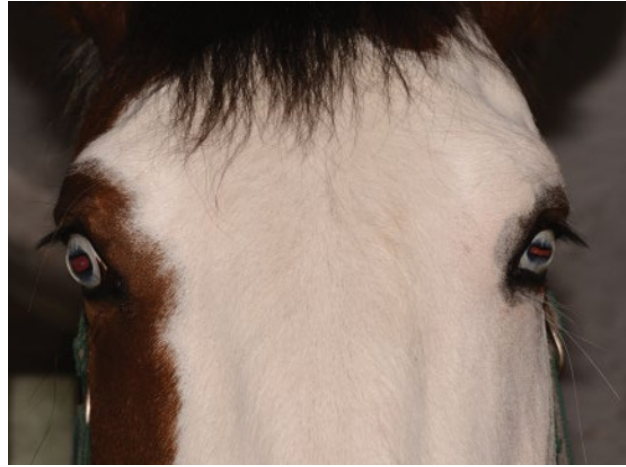

Figure 1.8 In this case, a different pupil diameter is present (anisocoria), with slight miosis in the left eye.

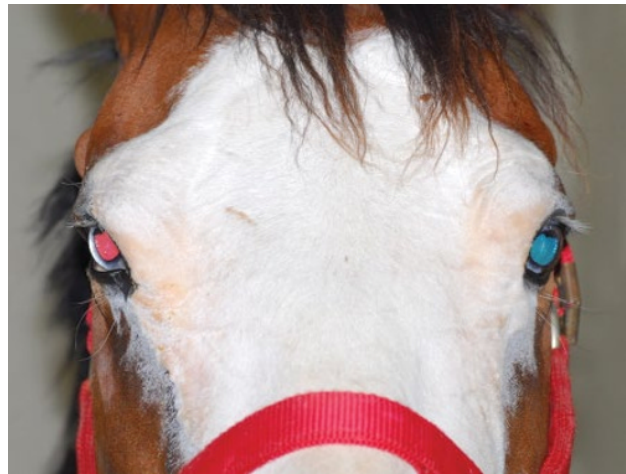

Figure 1.9 Anisocoria may be a normal finding in horses with bilateral heterochromia iridis or unilateral heterochromia iridis in which the larger pupil is ipsilateral to the heterochromic eye.

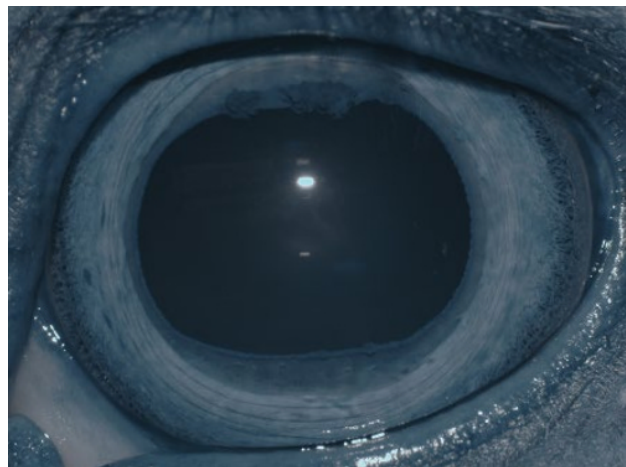


Figure 1.10 Pupil of the adult horse appears rounder when dilated. At infrared photograph, details of lateral and medial parts of the iridocorneal angle are more visible.

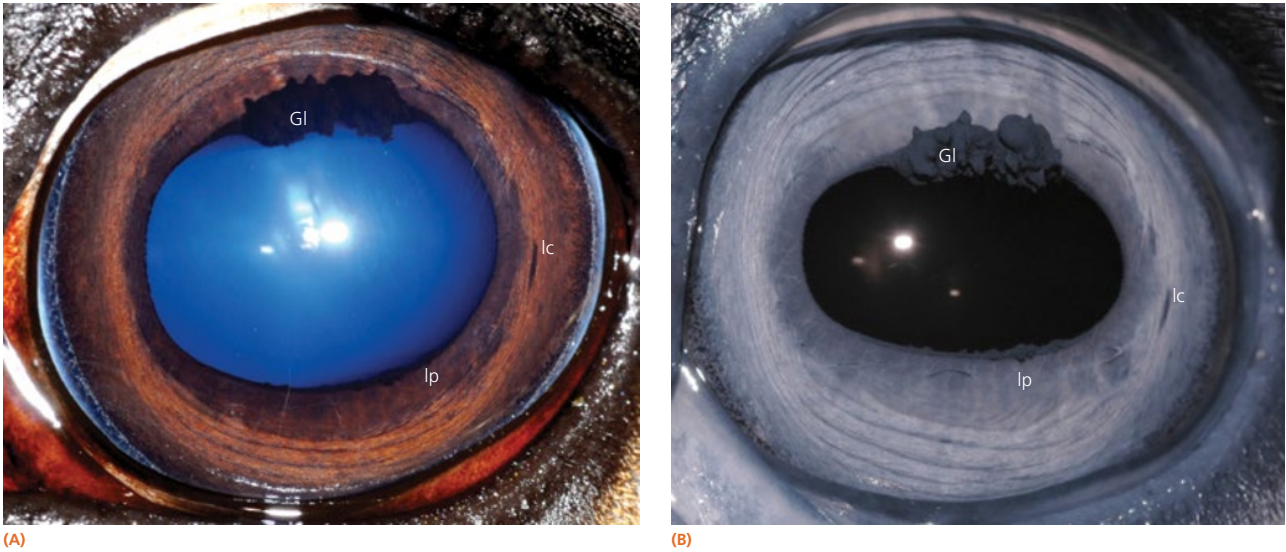


Figure 1.11 Normal anatomy of the pupil and corpora nigra in a horse. Granula iridica (GI) are present on the dorsal and ventral pupillary margins but are normally more prominent on the dorsal margin. The iris can be separated into a pupillary zone (Ip) and a more peripheral ciliary zone (Ic). (A) Color photograph. (B) Infrared photograph.

somewhat sluggishly and incompletely to light, in a biphasic manner [8, 19]. The first part is a brisk but small reaction, followed by the second slower complete movement. The magnitude and time of response depends on the brightness of the light source and the mental state of the horse. A very focal and bright light source is required to stimulate a rapid and complete response. Pupillary light responses are most vigorous if the beam is directed towards the visual streak in a direction that is temporal (lateral) and slightly dorsal to the optic disc. Consensual responses can be difficult to evaluate in the horse because they tend to be weaker than the direct response and can be awkward for an examiner to determine alone. The indirect PLR is less prominent because of decussation at the chiasm (85%) in the horse, which results in more efferent pupillomotor fibers that return to the ipsilateral side of the brain [6, 12, 20]. This is referred to as **dynamic contraction anisocoria** [17]. Evaluation for the consensual light reflex is unnecessary if the horse has vision and a direct response in both eyes. The consensual light reflex can be extremely valuable in evaluating problems when the posterior segment cannot be visualized (e.g., corneal edema, hyphema) for assessment of retinal function in the affected eye. Pupillary escape, a slight dilation that follows constriction under direct light stimulation, is a normal response in the horse [20].

Dazzle reflex

The dazzle reflex, in contrast to the cortically mediated menace response, is a subcortical reflex that requires function of the retina, CN II, rostral colliculus, possibly the supraoptic nuclei of the hypothalamus, CN VII, and orbicularis oculi [18–20]. A very bright focal light source is directed into the eye, and blinking or blepharospasm is a normal response. Care should be

taken if the light source generates heat, because this can be detected by the horse if the light source is close to the cornea and can also result in blepharospasm.

Palpebral reflex

Horses normally blink approximately 5–25 times per minute at rest [22]. The blink is synchronous between both eyes approximately 30–100% of the time [22, 23]. Two types of normal blinking occur in the horse at rest: complete and incomplete [23]. Incomplete blinking is most common and consists predominantly of upper eyelid motion downward [23]. Complete blinking is associated with an upward movement of the lower lid to meet the upper lid and is highly variable in occurrence [23]. The blink rate slows when the horse is sedated, anxious, or focused on an object of interest.

The palpebral reflex is elicited by touching the medial and lateral canthi and results in closure of the eyelids [18–20]. If CN V or CN VII is abnormal (e.g., facial nerve paralysis) or if the eyelids are unable to close (e.g., with severe trauma and swelling), the blink may be absent or incomplete.

Corneal reflex

The corneal reflex is elicited by lightly touching the unanesthetized cornea with a sterile cotton-tipped swab and results in closure of the eyelid and retraction of the globe [18–20]. This subcortical reflex occurs in response to a tactile or painful stimulus to the cornea. The afferent pathway of the corneal reflex is via the ophthalmic branch of CN V [20]. The result should be closure of the eyelid and retraction of the globe, mediated by CN VII and CN VI, respectively [20]. If CN V or CN VII is abnormal or if the eyelids are unable to close, the blink may be absent or incomplete. Corneal sensitivity can be quantitated by

a technique called **corneal esthesiometry**, which is described later in this chapter. Lack of corneal sensation may be the cause of corneal ulceration and other corneal abnormalities (see Chapter 7).

Autonomic (sympathetic and parasympathetic) nervous system

The autonomic nervous system is composed of two main divisions: the sympathetic and parasympathetic nervous systems (see Chapter 14). The sympathetic nervous system begins in the hypothalamus and extends down the intermediolateral cell columns of the spinal cord to synapse at C8 to T3. The axons from these cells exit the anterior nerve root of the spinal cord through the white ramus. The fibers (preganglionic fibers) course through the brachial plexus, through the thoracic inlet, and course cranially in the neck in the cervical sympathetic trunk. This trunk is associated with the vagus nerve forming the vagosympathetic trunk in the carotid sheath. Ventromedial to the tympanic bulla, the cervical sympathetic trunk separates from the vagus nerve and terminates in the cranial cervical ganglion. Postganglionic fibers proceed rostrally between the tympanic bulla and petrous temporal bone through the orbital fissure and form the sympathetic root of the ciliary ganglion [18–20]. Short ciliary nerves (along with contributory fibers to the long ciliary nerves) extend from the ciliary ganglion to the dilator muscle of the iris.

The sympathetic nervous system controls dilation of the pupils and other motor functions of the eyes and face. Damage to sympathetic innervation to the head may result in Horner's syndrome (miosis, ptosis, enophthalmos, increased sweating on the face and ear of the affected side, ipsilateral distention of facial blood vessels, and ipsilateral hyperemia of the conjunctiva and nasal mucosa) [24–30]. Chapter 15 offers a detailed description of the clinical signs and diagnosis of Horner's syndrome in horses. Causes reported in the horse include jugular vein and carotid artery injections, cervicothoracic spinal cord injury, cervical abscesses, guttural pouch disease or surgery, neoplasia or trauma of the neck and thorax, trauma to the vagosympathetic trunk, middle ear disease, traumatic lesions of the basisphenoid area, polyneuritis equi syndrome, equine protozoal myelitis of the cervical spinal cord, esophageal rupture, and trauma to the neck and thorax [8, 20, 24, 26, 27, 29–31].

The parasympathetic nervous system to the eye originates in the parasympathetic nucleus of the oculomotor nerve, located in the ventral part of the central gray matter next to the median plane and anteriorly to the general somatic efferent motor nucleus of the oculomotor nerve [32]. The fibers from this nucleus travel with the oculomotor nerve (CN III) and exit in the motor root of the ciliary ganglia where they synapse. The postsynaptic fibers travel to the eye in the short ciliary nerves to the constrictor muscles of the iris. Parasympathetic fibers also run with the facial nerve (CN VII) to the lacrimal gland to result in lacrimation when stimulated.

Restraint and sedation

Some horses can undergo an ocular examination without sedation, but most horses require sedation for a complete, detailed ophthalmic examination. Use of restraint and sedation depends on the temperament of the horse, availability of equipment, and comfort level of the handlers and examiner. Tranquilization with detomidine HCl 0.02–0.04 mg/kg, administered intravenously (IV) is preferred for ophthalmic examinations because it provides rapid tranquilization without an excitation phase (either on induction or during recovery) and a steady and low head position without movement (i.e., fine tremors). Xylazine 0.5–1 mg/kg IV with or without butorphanol tartrate (0.01–0.02 mg/kg IV) can also be used [8, 9]. Butorphanol is commonly added for painful procedures or additional restraint [8, 9]. However, xylazine can have a profound excitation phase on induction or recovery. Both butorphanol and xylazine are associated with fine head tremors, or head “jerks,” which can be very disruptive during slit-lamp biomicroscopy and minor procedures around the eye such as cytology collection. Addition of acepromazine (0.02–0.04 mg/kg IV; 20 mg IV in a 500-kg horse) [33] 10–15 minutes prior to or together with detomidine is recommended to avoid the fine tremors when additional tranquilization is needed for extended examination or minor standing surgical procedures. For prolonged examination, need of additional tranquilization, or standing surgical procedures, addition of romifidine (50–75 µg/kg IV) may be helpful [34, 35]. Additional restraint includes lip (rope or chain) and neck twitch (manual). Although these techniques are generally very effective for short-term restraint (i.e., less than 10 minutes), some horses react adversely to these techniques, so caution is advised when using them.

Regional nerve blocks

Two ophthalmic nerves are frequently denervated (“blocked”) during the equine ocular examination: the auriculopalpebral, or more precisely the palpebral branch of the facial nerve (CN VII), and the frontal (supraorbital) branch of the trigeminal nerve (CN V) [36, 37]. When these nerves are blocked, akinesia and anesthesia, respectively, of the upper eyelid occurs.

Regional akinesia

The most common nerve blocked is the palpebral branch of the auriculopalpebral nerve, which innervates the orbicularis oculi muscle, responsible in part for eyelid closure. The orbicularis oculi muscle in horses is very strong, and therefore akinesia of this muscle is required to open the eyelid for examination in many horses, especially horses that are in pain. It is extremely important in conditions in which the structural integrity of the globe can be compromised, because the pressure applied by the muscle during manipulation for examination or during blepharospasm could result in rupture of the globe. Akinesia of the eyelids may be induced for routine eye examination, diagnostic procedures (e.g., corneal cytology and culture), therapy (e.g., subconjunctival injections, placement of a subpalpebral lavage), and standing surgeries [36, 37].

A volume of 1–2 mL of an anesthetic is injected subcutaneously with a 25-gauge (G), 5/8-inch needle adjacent to the nerve, and the injection site is massaged to facilitate anesthetic diffusion [8, 9, 12, 36, 37]. Anesthetics most frequently used for eyelid blocks include 2% lidocaine HCl, which has an onset of action of 4–6 minutes and a duration of 60–90 minutes, and 2% mepivacaine, with an onset of action of 3–5 minutes and a duration of 90–120 minutes [8, 9, 12]. Procaine or bupivacaine can also be used. Repeated injections of anesthetic may result in a refractory phenomenon, requiring higher volumes of drug and longer times to achieve akinesia [12]. The auriculopalpebral nerve block results in paralysis of the orbicularis oculi muscle of the upper eyelid and variable paralysis of the lower eyelid for approximately 1–2 hours [8, 9, 12]. Duration of anesthesia can be prolonged with the addition of 1:10,000 epinephrine [12], but this is not usually required for most examinations or minor surgical procedures. Ptosis, narrowing of the palpebral fissure, and easy manual elevation of the upper eyelid should result [8, 9, 12]. Sensation to the eyelids and some palpebral function remains intact, so the horse can usually blink and continue to protect the cornea. Once the examination is concluded, if the horse is not blinking well, topical ophthalmic ointments should be used every 30 minutes to protect the cornea until palpebral function returns.

The auriculopalpebral nerve branches from the main trunk of the facial nerve, where it is protected by the parotid gland for the full length of the caudal border of the ramus of the mandible [12, 20]. It then emerges from beneath the gland just caudal to the caudal border of the condyle of the mandible, where it is covered by thin facial muscles and lies close to the rostral auricular artery and vein [12]. The branches then pass rostrally and dorsally to reach their destination (Figure 1.12).

The auriculopalpebral nerve can be blocked subfascially in the depression just anterior to the base of the ear where the caudal border of the coronoid process of the mandible meets the zygomatic process of the temporal bone. At this point, the nerve emerges from the parotid salivary gland and becomes subcutaneous on the lateral aspect of the dorsal tip of the coronoid process (Figures 1.12 and 1.13) [12, 36, 37].

The palpebral branch of the auriculopalpebral nerve can be blocked just lateral to the highest point of the caudal zygomatic arch, where the nerve can be palpated through the skin by running a finger forcefully over the dorsal border of the bone (see Figures 1.14 and 1.15) [36, 37]. The palpebral branch of the auriculopalpebral nerve can also be blocked where it lies on the zygomatic arch caudal to the bony process of the frontal bone (see Figures 1.14 and 1.15) [36, 37].

Regional anesthesia and analgesia

Sensation to the eyelids is provided by the ophthalmic and maxillary divisions of the trigeminal nerve (CN V) (Figure 1.14) [12]. The frontal, lacrimal, and infratrochlear nerves arise from the ophthalmic branch of CN V, and the zygomatic nerve arises from the maxillary branch of CN V [6, 12]. The frontal

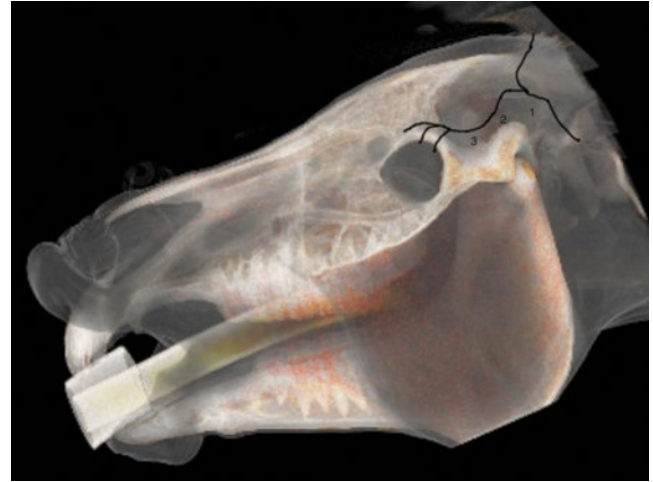


Figure 1.12 Three sites at which the auriculopalpebral nerve can be blocked: caudal to the posterior ramus of the mandible (1), dorsal to the highest point of the zygomatic arch (2), and where it lies on the zygomatic arch caudal to the bony process of the frontal bone (3).

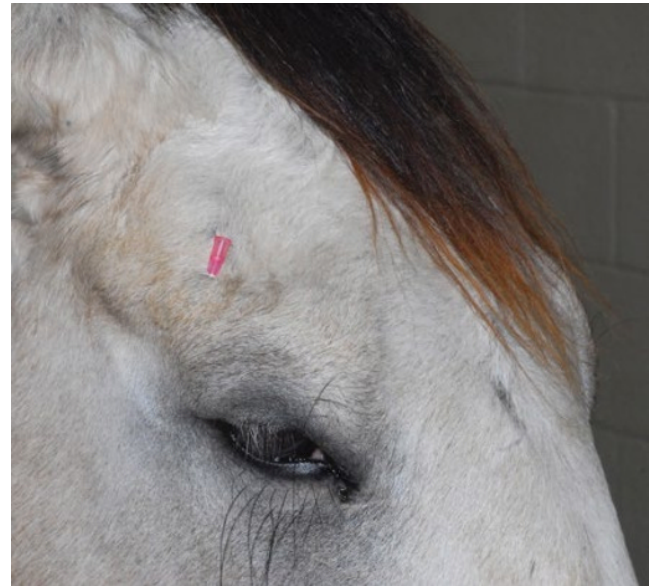

Figure 1.13 Location of the palpebral nerve block. A 25-G needle is inserted, and 1–2 mL of lidocaine or mepivacaine is injected subcutaneously.

(supraorbital) nerve innervates most of the central upper eyelid and is the only sensory block normally required for examination [12]. The lacrimal nerve provides sensory innervation for the lateral upper eyelid [12]. The infratrochlear nerve provides sensory innervation for the medial canthus [12]. The zygomatic nerve innervates the majority of the lateral lower eyelid [12]. The nasociliary nerve, a branch of the maxillary branch of CN V, provides sensory innervation to the cornea [12]. Anesthesia of these nerves is sometimes necessary for eyelid and conjunctival biopsies or simple surgeries, as well as subpalpebral lavage placement in the horse. The anesthetics most frequently used

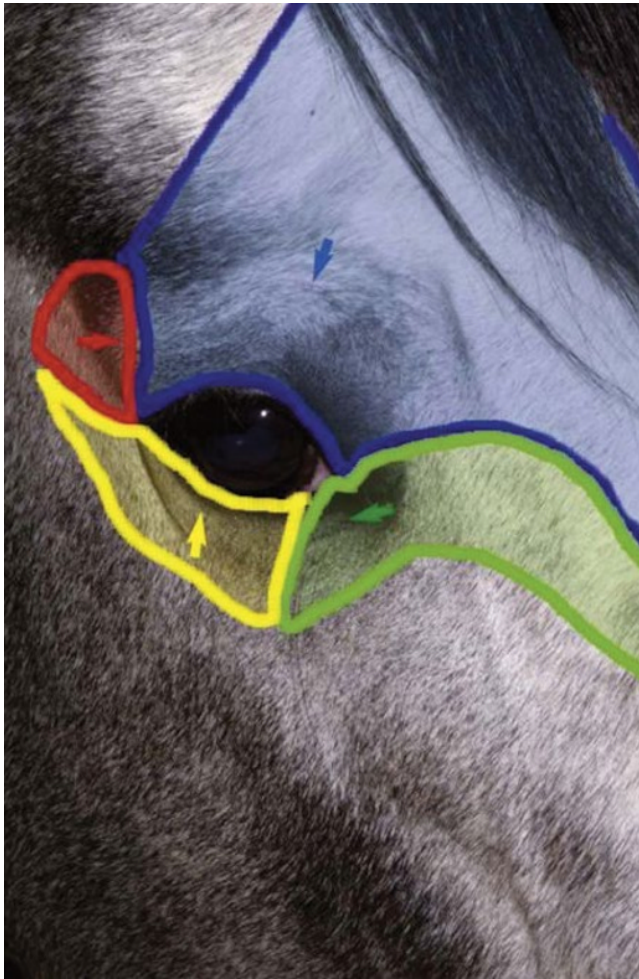


Figure 1.14 Sensation to the eyelids is provided by the ophthalmic and maxillary divisions of the trigeminal nerve (CN V). The frontal, lacrimal, and infratrochlear nerves arise from the ophthalmic branch of CN V, whereas the zygomatic nerve arises from the maxillary branch of CN V. The approximate areas of sensation that would be blocked with each nerve are indicated as follows: frontal (blue), lacrimal (red), zygomatic (yellow), infratrochlear (green).

are the same as those used for akinesia and include lidocaine HCl and mepivacaine.

The four main sensory nerve branches can be blocked directly as follows: the frontal (supraorbital) nerve is blocked as it emerges from the supraorbital foramen within the frontal bone (Figures 1.15 and 1.16) [12, 17]. This foramen can be easily palpated by placing the thumb below the dorsal orbital rim and the middle finger in the supraorbital fossa. The index finger is placed straight down, midway between the thumb and middle finger, to locate the supraorbital foramen (see Figure 1.16). A depression is usually palpable. A 25-G, $\frac{3}{8}$ -inch needle is then inserted subcutaneously over the foramen, and 1–2 mL of anesthetic is injected (Figure 1.17). Passing the needle into the foramen is not recommended because this may damage the supraorbital artery and vein, which exit the skull through the

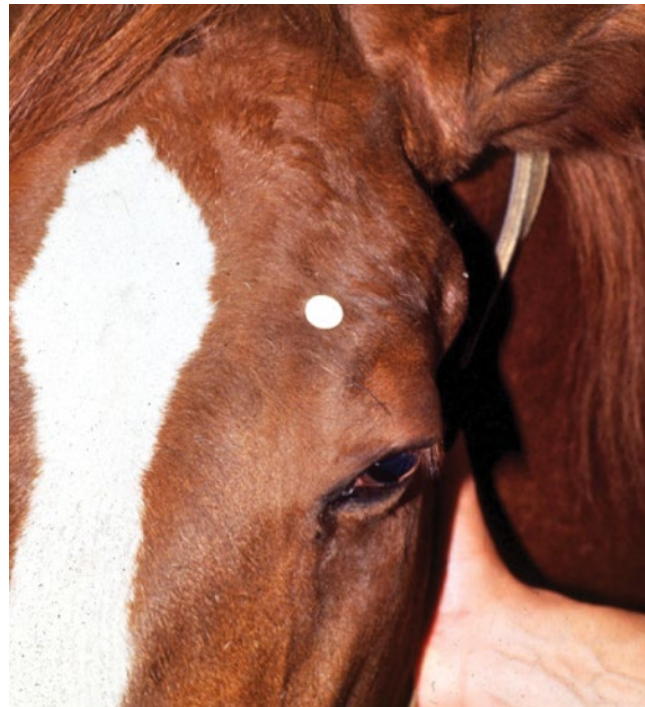

Figure 1.15 The frontal (supraorbital) nerve is blocked as it emerges from the supraorbital foramen within the frontal bone, as indicated by the white dot.

supraorbital foramen. Furthermore, if the needle inadvertently enters the periosteum surrounding the supraorbital foramen, this can be painful and the horse may react negatively. The frontal nerve is mainly sensory, but this block can result in partial upper eyelid akinesia as well, likely by further denervating the branches of the palpebral nerve [9].

The lacrimal nerve can be blocked by injecting 1 mL of lidocaine adjacent to the lacrimal notch, a depression that can be palpated on the dorsolateral bony orbital rim, or by using a line block along the lateral third of the dorsal orbital rim (Figures 1.14 and 1.18). The zygomatic nerve can be blocked with a line block along the ventrolateral orbital rim (Figures 1.14 and 1.19).

The infratrochlear nerve can be blocked as it runs through the trochlear notch located medially on the dorsal orbital rim (Figures 1.14 and 1.20). The notch can be palpated along the orbital rim.

Globe and orbit examination

Anatomy of the globe and orbit is reviewed in detail in Chapter 5. Initial examination of the globe and orbit should be made with the examiner positioned in front of the horse (see Figure 1.4), where symmetry between the eyes is carefully assessed. Palpebral fissure size and symmetry, relative globe position, and direction of the eyelashes are evaluated. The upper eyelashes of the healthy horse are nearly perpendicular to the cornea (see Figure 1.5A) [8]. A change in the angle between the eyelashes and the cornea may indicate blepharospasm, enophthalmos, exophthalmos, or ptosis (see Figure 1.5B) [8].

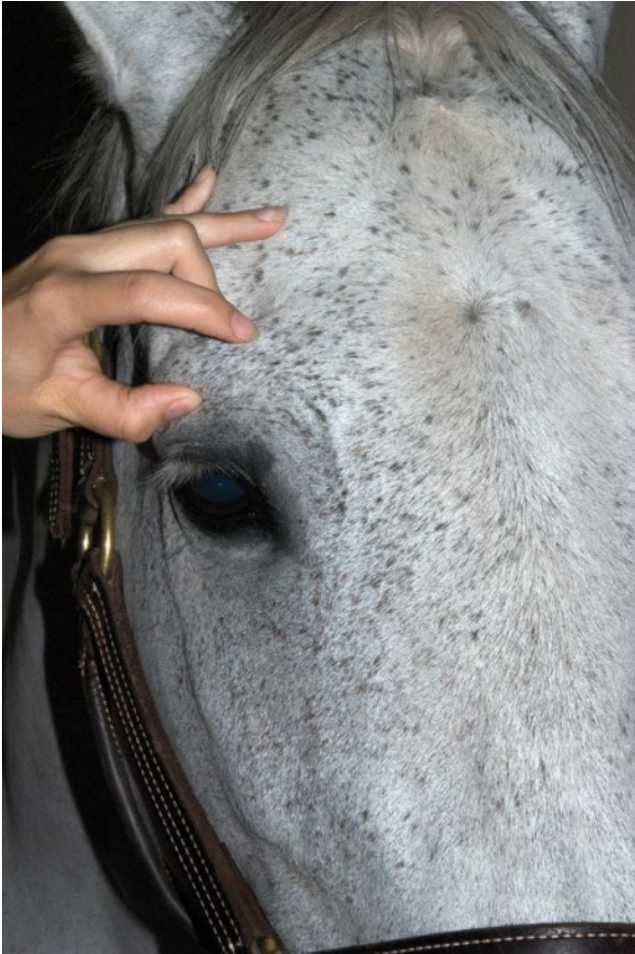

Figure 1.16 The supraorbital foramen can be palpated with the thumb below the dorsal orbital rim and the middle finger in the supraorbital fossa. The examiner then places the index finger straight down midway between the thumb and middle finger to locate the supraorbital foramen.

Apparent changes in globe size (e.g., buphthalmos (Figure 1.21)) should be differentiated from changes in globe position (e.g., exophthalmos (Figure 1.22)). Cornea globosa (Figure 1.23) has been reported in the Rocky Mountain horse and may be difficult to distinguish from buphthalmos [38, 39]. The orbit should be examined by observation, palpation of the bony orbital rim, and retropulsion of the globe through a closed eyelid [4, 8, 9]. Forceful manipulation of the eyelid and retropulsion should not be performed if the structural integrity of the cornea or globe may be compromised.

Eyelids and conjunctiva examination

Anatomy of the eyelids and conjunctiva is reviewed in detail in Chapter 6. Examination of the eyelid should include assessment of function and detailed examination using diffuse illumination with magnification (e.g., using a slit-lamp biomicroscope). The periocular tissues including the eyelids, conjunctiva, sclera, and nictitans should be inspected with transillumination [17], the technique of direct focal illumination for inspection of the

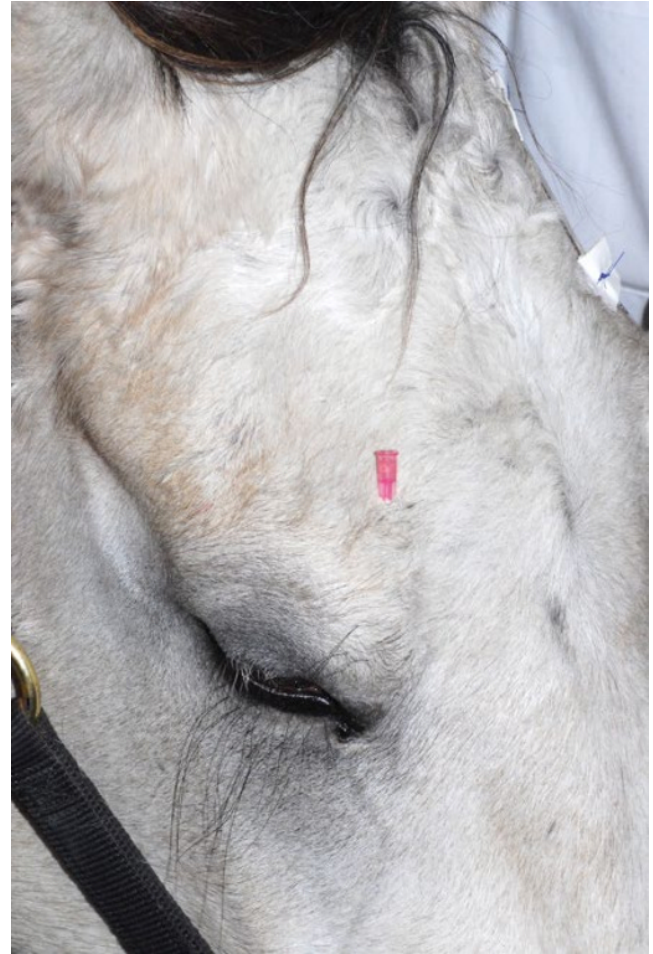

Figure 1.17 A 25-G, 5/8-inch needle is inserted into or just over the foramen.

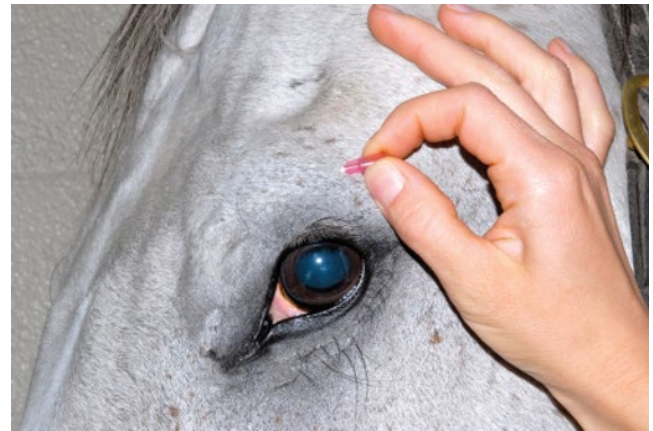

Figure 1.18 The lacrimal nerve can be blocked by using a line block along the lateral third of the dorsal orbital rim.

anterior structures of the eye. It can be performed with a Finnoff transilluminator (Welch-Allyn, Skaneateles Falls, NY), direct ophthalmoscope, slit-lamp biomicroscope, or even a penlight. Eyelids should be examined for position, movement,

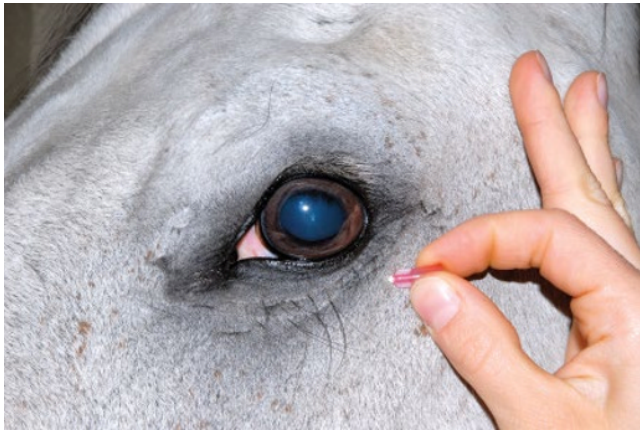

Figure 1.19 The zygomatic nerve can be blocked with a line block along the ventrolateral orbital rim.

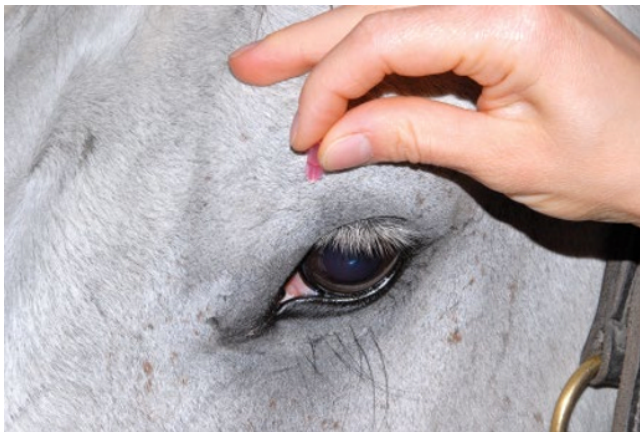

Figure 1.20 The infratrochlear nerve can be blocked as it runs through the trochlear notch, located medially on the dorsal orbital rim. The notch can be palpated.

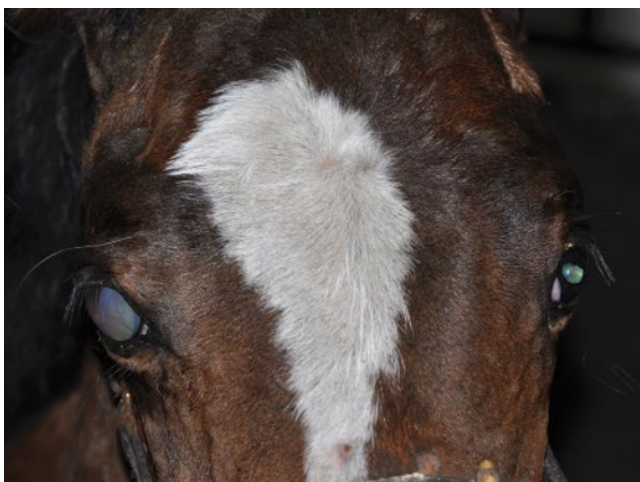


Figure 1.21 Right eye congenital glaucoma and hydrophthalmus in a foal.



Figure 1.22 Exophthalmos of the right eye of a horse with a retrobulbar mass.

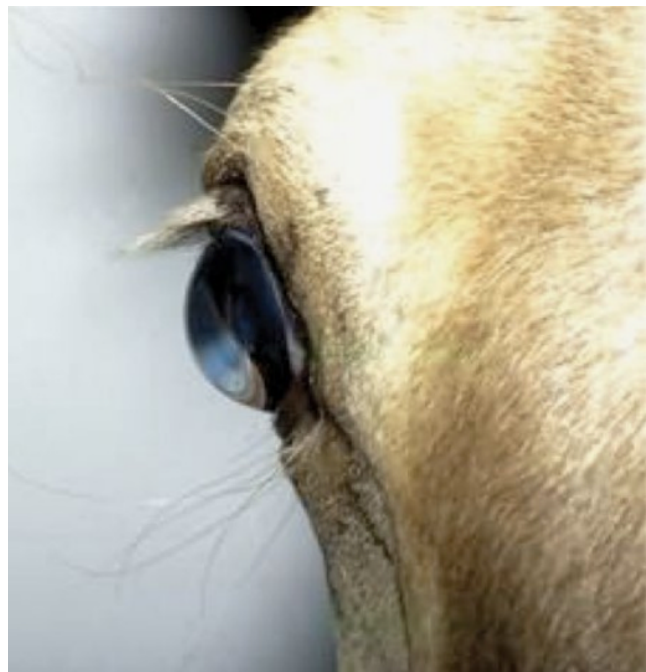


Figure 1.23 Corneal globosa of a Rocky Mountain horse with multiple congenital ocular anomalies. (Source: Photograph courtesy Dr David Ramsey.)

and conformation prior to the use of eyelid blocks [4, 8, 9] Attempts to forcefully elevate the upper eyelid should be avoided if a palpebral nerve block has not yet been performed, and each eye should be examined with minimal handling of the adnexal tissues. Culture and cytology should be collected prior to instillation of any medications (see section **Culture and cytology of corneal lesions** and Chapter 3). Biopsy of the eyelid or conjunctiva should be considered if indicated (see Chapter 6).

Lacrimal and nasolacrimal system examination

See anatomy of the lacrimal and nasolacrimal system in Chapter 6. Assessment of the lacrimal system is done by microscopic examination of the tear film via slit-lamp biomicroscopy

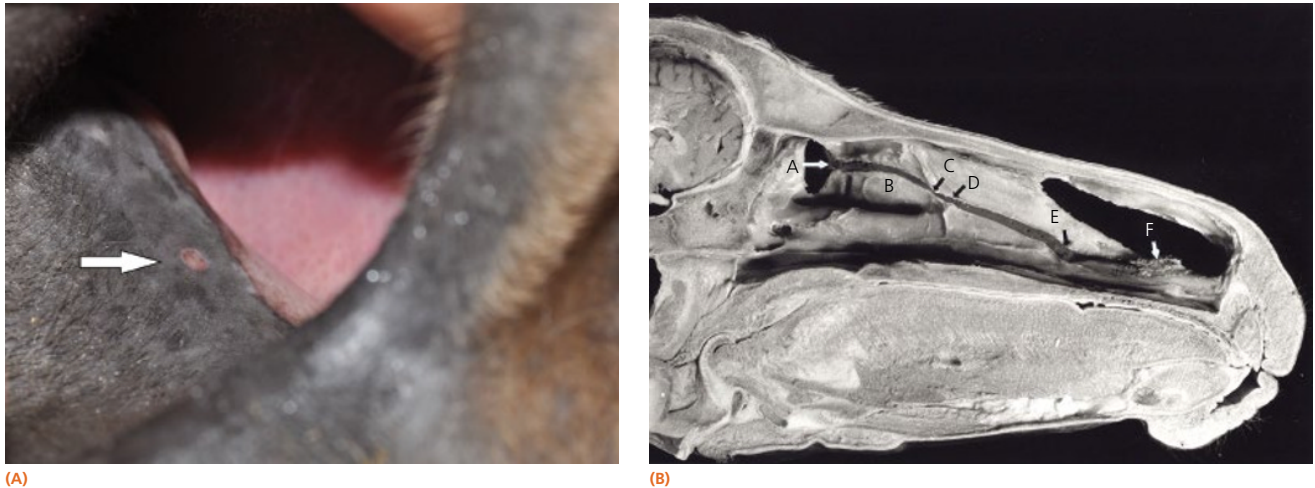

Figure 1.24 (A) Normally a single distal punctum of the nasolacrimal system is present and can be located in the skin of the floor of the nostril near the mucocutaneous junction (arrow). (B) Methyl methacrylate cast of the left nasolacrimal duct in the horse with the medial bony orbit and medial wall of the lacrimal canal removed. (A) Lacrimal sac. (B) Duct within the lacrimal canal. (C) Narrowing of nasolacrimal duct at the exit from the lacrimal canal. (D) Exit of the duct from the lacrimal canal. (E) Duct pressed laterally by cartilaginous plate in alar fold. (F) Duct within basal fold. (Source: (B) Latimer et al., 1984. Reproduced with permission from American Veterinary Medical Association.)

(or other means of magnification) and adjunctive diagnostic tests, such as the Schirmer tear test (STT), the phenol red thread (PRT) tear test and Tear film Break-Up Time (TBUT) test. The examiner should also inspect the openings of the proximal (eyelid) and distal (nasal) nasolacrimal puncta (Figure 1.24).

The STT is used commonly to measure aqueous tear production [40–43]. In the test, a filter paper strip is placed in the lower conjunctival sac, and wetting is then measured in millimeters per 60 seconds (Figure 1.25). Commercial filter paper strips available include standardized Sno-Strips (Akorn) and Color Bar (Eagle Vision/Schering-Plough). Strips can also be made from Whatman filter paper (#40, 5 × 40 mm with a notch 5 mm from the end) [12]. The STT I, in which no topical anesthesia is used, measures the approximate amount of basal and reflex tearing. The STT II, performed after the application of topical anesthesia, theoretically only measures basal secretion of aqueous tears. Some residual tear volume may make both of these measurements slightly inaccurate. The STT should be performed before manipulation of the eye and orbit during examination to minimize reflex tearing. There are no reports of the effect of an auriculopalpebral nerve block on the STT in horses.

The PRT test consists of a thread of 75 mm in length with a fold 3 mm from the end, impregnated with phenol red, which is a pH indicator. The thread is placed in the lower conjunctival fornix for 15 seconds. The pale yellow thread turns orange due to the alkaline tears composition. Even if the main advantage of this test is that it can be used in small eyes (e.g., nondomestic species), it has been used in horses too, with a mean tear production of 30.22 ± 0.99 and 31.00 ± 1.4 in healthy Arabian and Thoroughbred horses [44]. The TBUT test is a noninvasive ocular diagnostic test that allows an assessment of the quality of the precorneal tear film (mucin and/or lipid layers) by observing

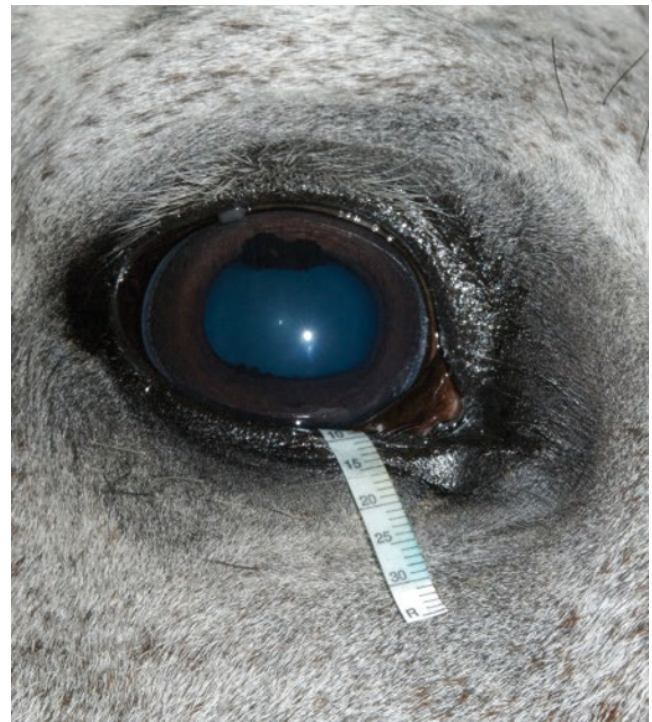

Figure 1.25 The STT is used to measure aqueous tear production. In the test, a filter-paper strip is placed in the conjunctival sac, and wetting is then measured in millimeters per 60 seconds.

its stability over the corneal surface. It corresponds to the time required for the ocular surface to lose cohesive surface wetting after each blink. To perform the TBUT test, fluorescein solution is applied to the corneal surface, the horse is allowed to blink, and then the eyelids are held open until a dry spot forms, which

appears dark compared to the fluorescein green color in the tear film. The observation of these dark areas is facilitated by using a slit-lamp biomicroscope with the cobalt blue filter. Mean basal TBUT values reported in horses are 8.3 ± 1.3 seconds [45]. Topical use of tetracaine HCl eyedrops in a normal horse results in a quicker TBUT [45].

Deficiencies in aqueous tear production have rarely been reported in the horse [23, 42, 43, 46–51]. This may be because the STT is not a part of the routine ophthalmic examination in the horse. Specific indications to perform STT include evidence of CN VII dysfunction (e.g., after trauma, facial paralysis), desiccated cornea or conjunctiva, presence of tenacious mucoid discharge, and presence of unexplained corneal vascularization or ulceration. Keratoconjunctivitis sicca (KCS) is most commonly the result of CN V or VII trauma but has also been reported in cases of fractures of the mandible and stylohyoid bone, post anesthesia, locoweed poisoning, eosinophilic dacryoadenitis, hypothyroidism, and in association with corneal stromal sequestration [23, 41, 43, 46–51].

The effects of age, season, gender, environment, sex, time of day, and placement of strips on STT results in healthy horses and ponies have also been reported [40, 42]. In general, the STT value in the horse is much greater than that in cats and dogs [41, 52, 53]. STT values are highly variable between eyes and between the same eye during different times of the day, and this appears to be unrelated to signalment, housing, or season [40]. One study found a diurnal variation in horses housed in a 12-hour light and 12-hour dark setting [42]. These horses had STT values that gradually increased during the light phase, peaked at 4–6 hours, then decreased during the dark phase [42]. Healthy horses have been reported to have an STT I range of 11–>30 mm wetting/min and 15–20 mm/30 s. Both sick and healthy neonatal foals have been reported to have lower STT values than adults [54, 55]. STT I values for sick neonatal foals (14.2 ± 1 mm wetting/min) and healthy neonatal foals (12.8 ± 2.4 mm/min) were not significantly different but were lower than STT I values from healthy adult horses (18.3 ± 2.1 mm/min) [54, 55].

Comparisons of STT I and STT II values revealed minimal differences in one study (i.e., STT I and STT II values of 12.7 ± 9.1 mm wetting/min and $9.9 \text{ mm} \pm 4.25$ mm wetting/min) [53], while the second study did not reveal a difference between STT I and STT II values [40]. This is in contrast to the dog, in which the STT I value is significantly higher than the STT II value [56]. Sedation with xylazine does not affect the STT value; however, general inhalant anesthesia with halothane does lower the STT value for up to 3 hours [41].

Borderline STT measurements (e.g., measurements of 10–15 mm wetting/min) should always be repeated. Comparison of tear test results between the two eyes should be cautiously interpreted in clinical assessment of decreased tearing [40]. In general, repeatable measurements of less than 10 mm wetting/min should be considered abnormal in conjunction with clinical signs [4]. See Chapters 6 and 7 for more information on KCS.

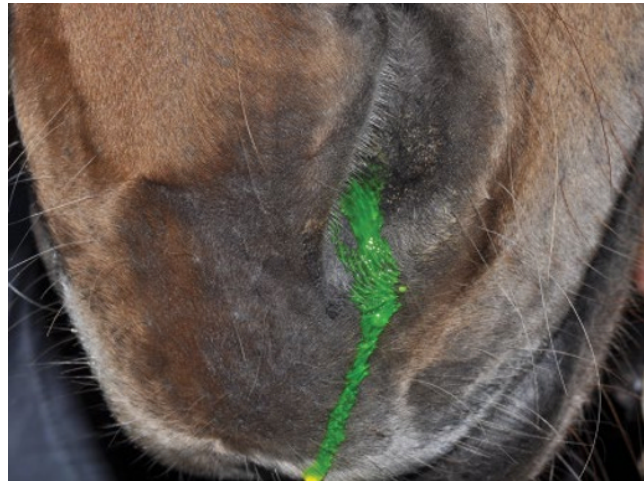
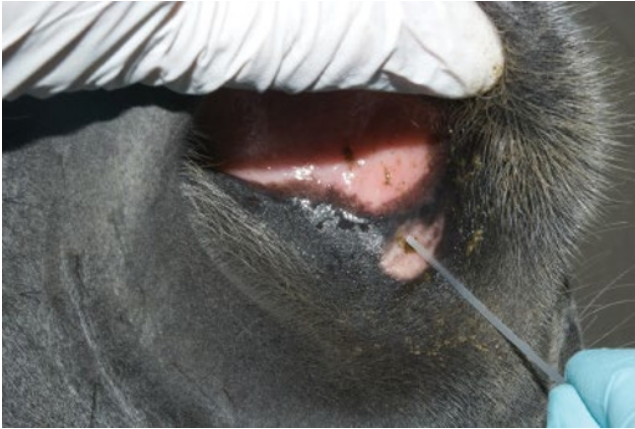
Figure 1.26 Passage of fluorescein dye to the distal punctum in the nares (Jones test I) is timed and should occur within 5 minutes but may take up to 20 minutes in the horse.

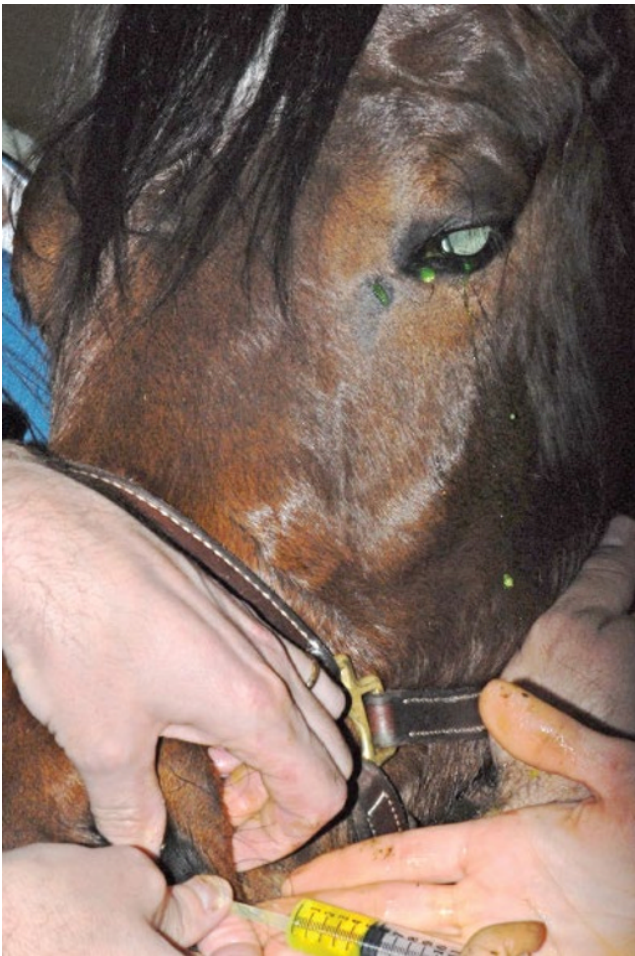
Nasolacrimal duct patency

The physiologic patency of the nasolacrimal system can be evaluated with topical sodium fluorescein, which is not rinsed from the eye [12]. Passage of the fluorescein to the distal puncta in the nares (Jones test I) is timed and should occur within 5 minutes but may take up to 20 minutes (Figure 1.26) [17]. The required time for passage is influenced by the amount of fluorescein placed, tear production, and length of the individual horse's nasolacrimal system [17]. A positive test result is definitive for a patent nasolacrimal duct but does not prove that both proximal puncta are patent [17]. A negative test result is only suggestive of a problem and may even be normal in the horse because of the large volume capacity of the nasolacrimal duct [17, 57, 58]. However, the nasolacrimal duct should be irrigated if the dye fails to appear and clinical signs suggest a problem such as epiphora (watery ocular discharge) without an obvious cause, mucopurulent ocular or nasal punctal discharge, or dacryohemorrhage [17, 57, 58].

Irrigation of the nasolacrimal duct can be performed retrograde (i.e., from the distal nares opening) or normograde (i.e., from the proximal eyelid puncta) [12]. Sedation is usually required to perform either procedure in the horse. Retrograde irrigation through the nasal meatus to the nasolacrimal duct is easiest to perform (Figure 1.27) because of the larger size of the opening [17, 58]. The distal nasolacrimal puncta can usually be cannulated by a 5 or 6 polyethylene urinary catheter [17]. Suitable catheters are 4- to 6-French canine urinary catheters, 5-French feeding tubes, or polyethylene tubing [17]. The largest catheter that will pass through the bony canal in an adult horse is a 6-French urinary catheter [17]. The tip of the catheter, after it has been coated with lidocaine gel, is inserted into the distal punctal opening for a distance of at least 5 cm. Digital pressure should be applied to the opening to close it and prevent normograde loss of fluid. A 12- to 20-mL syringe previously filled with



(A)



(B)

Figure 1.27 Retrograde irrigation through the distal opening to the nasolacrimal duct is easiest to perform. (A) The tip of the catheter, after it has been coated with lidocaine gel, is inserted into the distal punctal opening. Digital pressure should be applied to the opening to prevent normograde loss of fluid. (B) The 12-mL syringe, previously filled with eyewash, is attached; gentle irrigation of the nasolacrimal duct is performed until fluid exits the proximal punctum near the medial canthus of the eye.

Box 1.5 Supplies needed for irrigation of the nasolacrimal duct.

Retrograde irrigation

- Lidocaine gel for retrograde
- Open-ended tomcat catheter, 4- to 6-French polyethylene urinary catheter, 5-French feeding tubes, or polyethylene tubing
- A 12- to 20-mL syringe
- Sterile eyewash or balanced salt solution

Normograde irrigation

- Topical anesthetic (proparacaine HCl)
- Open-ended tomcat catheter, lacrimal cannula, 18- to 20-G IV cannula
- A 12- to 20-mL syringe
- Sterile eyewash or balanced salt solution

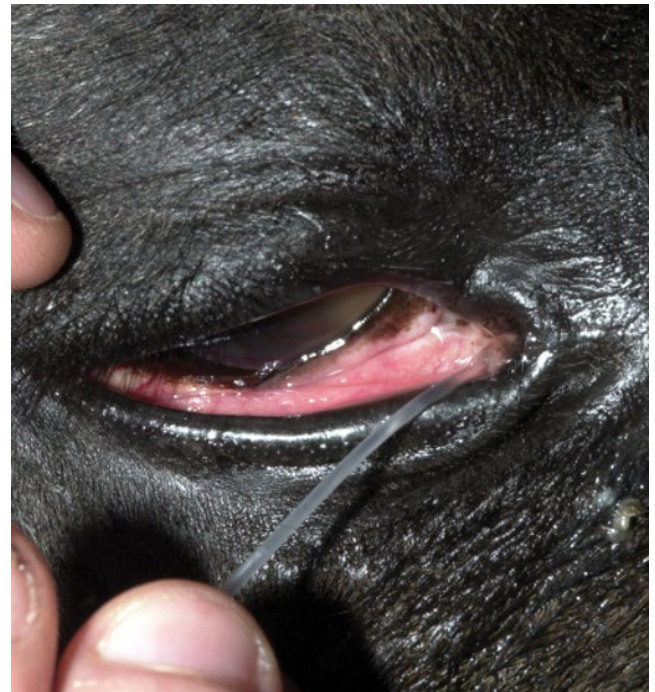


Figure 1.28 Normograde irrigation from the proximal puncta should be attempted if the result of the Jones test I is negative and the duct cannot be irrigated from the distal nasal puncta. Catheterization of the proximal punctum using an open-ended tomcat catheter in the lower eyelid is demonstrated.

eyewash is attached, and gentle irrigation of the nasolacrimal duct is performed until fluid exits the proximal puncta near the medial canthus of the eye. Sneezing by the horse is common during this procedure and may be violent. A list of supplies needed to perform nasolacrimal duct irrigation can be found in Box 1.5.

If retrograde irrigation is unsuccessful, then normograde irrigation from the proximal puncta should be attempted with a lacrimal cannula, open-ended tomcat catheter, 18- to 20-G IV cannula, or teat tube syringe (Figure 1.28) [17]. The punctum in

the lower eyelid is usually slightly larger and easier to cannulate than the punctum in the upper eyelid [17]. Gentle pulse pressure may be required to unblock an obstructed duct. Excessive force in the placement of the catheter or during irrigation should be avoided because significant damage to the nasolacrimal duct could result [17]. Ducts that are compromised by a foreign body or other anatomic obstruction (e.g., after trauma, mass effect) may not be effectively irrigated [59]. Skull radiographs or computed tomography (CT) scans and a contrast dye study (e.g., dacryocystorhinography) should be performed next if the duct cannot be irrigated. Endoscopic examination of the nasolacrimal duct also has been described [60]. See descriptions of these diagnostic techniques in the Chapter 2.

Cornea and sclera examination

The anatomy and diseases of the equine cornea are described in Chapter 7. To examine the cornea of the horse, diffuse and focal direct illumination (or transillumination) with magnification is used first, followed in most cases by biomicroscopy using a slit-lamp. The corneal examination should be performed with the observer located rostral to the eye. Light directed diagonally across the cornea will reveal opacities of the cornea against the dark background of the pupil [17].

The Purkinje–Sanson reflexes are three reflections from the eye produced by the light source during transillumination (Figure 1.29) [17]. Disease may alter the sharpness and location of these reflexes. The first, largest, and most anterior originates from the cornea. The second originates from the anterior lens capsule, and the third and most posterior originates from the posterior lens capsule. If a slit-lamp biomicroscope is used, two corneal reflexes are seen, one from the anterior surface and the other from the endothelium [17]. The corneal and anterior lens

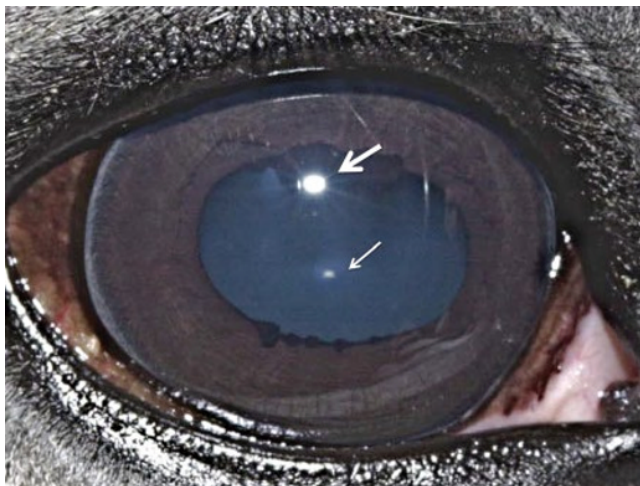


Figure 1.29 The Purkinje–Sanson reflexes are three reflections produced by the light source during transillumination. The largest is produced by the cornea (**larger arrow**). The second is produced by the anterior lens capsule (**smaller arrow**). The third is not easily visible and is produced by the posterior lens capsule.

capsule reflexes are virtual and noninverted and will move in the same direction as a change in the light position. The image on the posterior surface is real and inverted and will move in the opposite direction to the light [17]. The images are valuable in determining corneal clarity, depth of the anterior chamber, thickness and position of the lens (after mydriasis), and in locating lesions within the lens [17].

Biomicroscopy for corneal examination

The technique of biomicroscopy, in which a slit-lamp binocular microscope with an external pivoting light source is used, is the same for horses as for humans and small animals and has been well described elsewhere [12, 61–64]. Slit-lamp biomicroscopy improves visualization and localization of lesions of the cornea, anterior chamber, lens, and anterior vitreous by means of transillumination and retroillumination [12]. It can also be used to assess corneal thickness (i.e., pachymetry), anterior chamber depth, and aqueous flare [12].

The availability of portable handheld models of the slit-lamp biomicroscope has made biomicroscopy for equine ophthalmology easy and efficient. Portable models are available from Clement-Clark, Kowa, Nippon, Dioptrix, and Zeiss. The Kowa SL-14, SL-15, and SL-17 ($\times 10$ or $\times 16$ magnification) is light and powered by battery, and therefore of excellent use in examination of a horse. However, lack of magnification above $\times 16$ and inherent movement of the examiner and horse limit the ability to see fine structure and lesions. An alternative to a biomicroscope is using magnification (i.e., $\times 2.5$ – 3.0 magnifying head loupes) and the slit beam on the direct ophthalmoscope. Very small “slit-lamps” are also made by Heine (HSL 150 (Heine USA, Dover, NH); Eidolon Hand Held Slit Lamp Model 510L (Eidolon Optical LLC, Natick, MA)) that resemble a penlight with a magnifier on the end (Figure 1.30). Although these instruments are inexpensive and portable, their lack of magnification and illumination limits their usefulness [12].

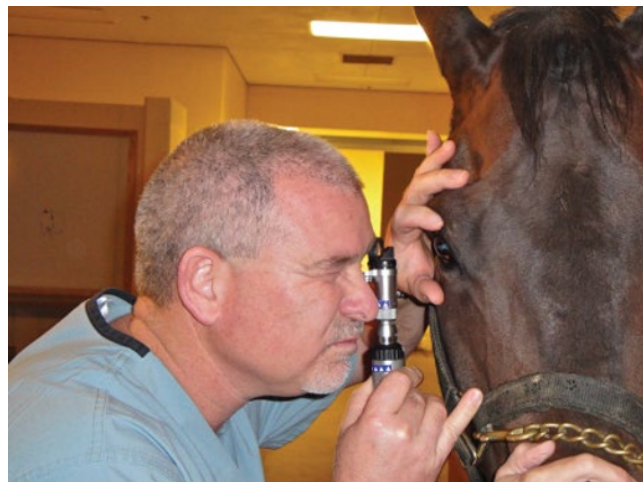

Figure 1.30 Use of a small, portable slit-lamp (Heine Handheld Slit Lamp (Heine USA, Dover, NH)). (Source: Photograph courtesy Dr David Wilkie.)

The light beam of the biomicroscope should be angled at 20–45 degrees from the axis of the microscope and thus the visual plane of the observer (Figure 1.31). The light beam width, length, orientation, and color can then be modified by a series of diaphragms and filters [12]. The focal distance of the instrument is 7–10 cm, and fine focus is achieved by moving either toward or away from the eye within this range [12].

Particular attention needs to be used during biomicroscopy examination in horses, as during this examination the examiner's eyes are in contact with the slit-lamp without direct visualization of the entire animal. In this situation, sudden head movement could be very dangerous for the examiner and for the instrument as well. To avoid possible trauma from the horse, it is important to stay in contact with the horse's head with your hand (Figure 1.31). It is also very important to remove glasses, if used, during this examination.

The initial examination of the horse should proceed with diffuse illumination: a wide, low-intensity slit beam should be used, and the microscope should be defocused from the light [12]. The surfaces of the eyelids, cornea, conjunctiva, and iris should be inspected. With the use of low magnification, a broad slit beam is focused on the cornea, creating a parallelepiped (i.e., a three-dimensional section) of illuminated tissue [12, 61]. This allows visualization of transparent structures such as the cornea and lens in three dimensions. In the cornea, the anterior surface, stroma, and posterior surface of the cornea can be visualized [61]. Nontransparent structures such as the sclera only yield a magnified two-dimensional surface or external view. The slit beam is then narrowed and intensified to reveal a two-dimensional cross-section of the cornea and lens, allowing the examiner to accurately determine lesion depth and axial positioning [61]. This is extremely important in evaluating the depth of corneal lesions (e.g., stromal ulcerative keratitis, stromal abscesses) in the horse.

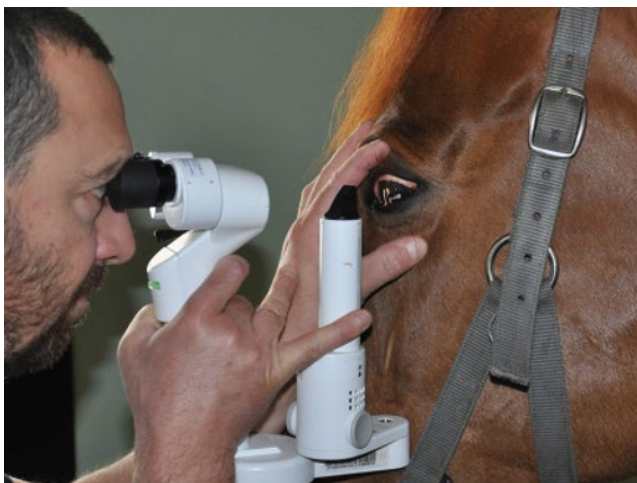

Figure 1.31 The light beam of the biomicroscope should be angled at 20–45 degrees from the axis of the microscope (Kowa SL-17) and thus the visual plane of the observer. The examiner should always be in contact with the horse's head, avoiding possible trauma from head movements.

Direct and indirect retroillumination are performed by reflecting the slit beam from deeper structures while focusing on more superficial structures [61]. Other techniques that can be performed with slit-lamp biomicroscopy, such as specular reflection, are difficult to impossible in a horse because of continuous slight ocular movements.

Culture and cytology of corneal lesions

See Chapter 3 and online material for detailed information on collecting and interpreting ocular cultures and cytology.

Ophthalmic dyes

Topical ophthalmic dyes are routinely used in veterinary medicine to aid in the diagnosis of corneal, conjunctival, and nasolacrimal diseases. Commonly used topical ophthalmic dyes include sodium fluorescein, rose bengal, lissamine green, alcian blue, trypan blue, and methylene blue [12, 65–67]. Sodium fluorescein and rose bengal are the two most commonly used dyes in clinical veterinary ophthalmology [12, 66, 68, 69]. Indications for the use of topical ophthalmic dyes in the horse include determining the health and integrity of the precorneal tear film, corneal epithelium, and conjunctival epithelium, and the physiologic flow of the nasolacrimal system. Intravenous sodium fluorescein is used to perform fluorescein angiography and is discussed in Chapter 2.

Sodium fluorescein

The most common use for topical sodium fluorescein is detecting ulcerative keratitis, but it will also stain conjunctival ulcerations and abrasions. In a corneal ulceration, the hydrophilic fluorescein binds to the corneal stroma but not to the lipophilic epithelium or to Descemet's membrane (Figure 1.32). Small quantities can also pool or diffuse through intact epithelial cell intercellular spaces to reveal weakly staining epithelial

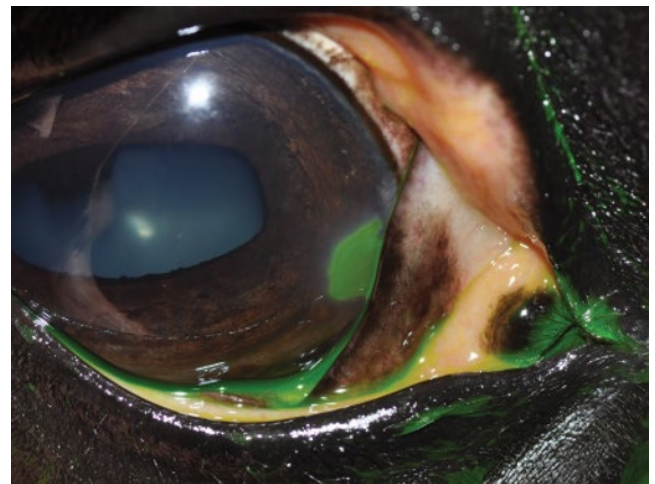


Figure 1.32 In a corneal ulceration, the hydrophilic fluorescein binds to the corneal stroma but not to the epithelium or to Descemet's membrane, resulting in a green stain.

microcysts and partial-thickness microerosions [12, 67]. From the stroma, the dye can then readily pass through Descemet's membrane and the corneal endothelium to enter the aqueous humor and can be quantified (e.g., by fluorophotometry).

Fluorescein staining of the cornea is indicated for almost every condition in the horse involving its eye and orbit—a red or painful eye, discharge from the eye, an obvious corneal irregularity, history of ocular trauma—and for assessment of the tear film stability (TBUT) and physiologic nasolacrimal function. Fluorescein is available as a sterile 0.5–2% alkaline solution or as a sterile impregnated paper strip [70]. The impregnated paper strips should be used for topical application, because the solutions have been associated with bacterial contamination [71]. Other equipment needed to perform the stain includes sterile eyewash solution and a 3-mL syringe with a 25-G needle. The easiest method of applying topical fluorescein to horses is to place a sterile fluorescein strip in a 3-mL syringe, fill the syringe with sterile eyewash, replace the plunger, and then squirt the solution through the **hub** of a 25-G needle from which the needle has been manually broken off (Figure 1.33) [8, 17]. After application, the eyelids should be closed or the animal allowed to blink to distribute the stain evenly across the ocular surfaces. Excess fluorescein can be removed with gentle irrigation with eyewash if required. Alternatively, undiluted fluorescein applied topically may allow for better visualization of corneal epithelial erosions or early corneal trauma. The use of an ultraviolet or blue light, usually available on a direct ophthalmoscope or the slit-lamp biomicroscope, may improve visualization of the stain. False-positive results may occur after the use of proparacaine topical anesthesia or if direct contact between the paper strip and cornea occurs, which may leave a mark that resembles a corneal defect [12, 17].

Fluorescein may also be used to detect leakage of aqueous humor through the cornea (i.e., the Seidel test) [12, 17]. The Seidel test can be used to detect full-thickness corneal injuries or determine whether a corneal suture is leaking. The application of sodium fluorescein without subsequent irrigation results in a high dye concentration in which the dye fluoresces at wavelengths closer to the yellow and orange spectra. With or without gentle pressure on the cornea, aqueous leakage locally dilutes the fluorescein, and the dye fluoresces green [12].

Rose bengal

Rose bengal (i.e., tetrachloro-tetra-iodo-fluorescein) has been used to aid in the diagnosis of precorneal tear film disorders, mucin precorneal film deficiencies, and superficial corneal epithelial abnormalities in horses (Figure 1.34). It can be used primarily or after sodium fluorescein application. Rose bengal stains dead and degenerating cells and mucus [67]. However, rose bengal has a dose-dependent ability to stain normal cells, and this ability is normally blocked by tear film components [12, 67, 72]. Therefore stain uptake may indicate tear film abnormalities, such as a mucin deficiency, more accurately than cell viability [12, 67, 72]. Rose bengal, like sodium



Figure 1.33 The easiest method of applying topical fluorescein to horses is to place a sterile fluorescein strip in a 3-mL syringe, fill the syringe with sterile eyewash, replace the plunger, then squirt the solution through the hub of a 25-G needle from which the needle has been manually broken off.

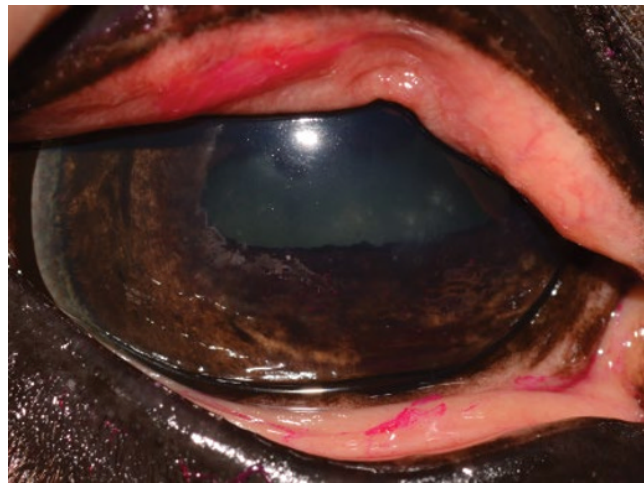


Figure 1.34 Rose bengal positive stain of epithelial multipunctate lesions suspected of superficial primary fungal infection.

fluorescein, is available as both an impregnated paper strip and a solution [12, 66, 69]. Use of the 0.5% or lower concentrations can minimize the irritation that can be associated with the 1% solution [12]. The dye has also been shown to be toxic to corneal epithelium at routine concentrations [73]. Slit-lamp biomicroscopy may be necessary for adequate visualization of rose bengal stain.

The use of rose bengal would be indicated in the horse in any of the conditions in which corneal or conjunctival ulceration is suspected, but especially when a viral or fungal cause is suspected. One report suggested that rose bengal staining is present as a result of ocular surface damage in the presence of keratomycosis (Figure 1.34) [74]. Specimens obtained from horses with painful eyes should be stained with both fluorescein and rose bengal; superficial keratitis may be negative for fluorescein but positive for rose bengal [23, 74].

Other ophthalmic dyes

Lissamine green is an organic acid dye widely used in human ophthalmology [67]. It is a true vital dye as it does not stain healthy epithelial cells even in the absence of the tear film, differently from rose bengal. Despite this difference, lissamine green has a similar staining pattern to rose bengal and it has been used in the case of KCS, with the advantage that it is less toxic and irritant than rose bengal [69, 75, 76]. Different dyes can be applied alone or at the same time, as mixing of the dyes does not affect staining properties [69, 77].

Trypan blue, an azo dye derived from tuluidine, is widely used in human and veterinary cataract surgery, as it stains the anterior lens capsule and thus helps its visualization during capsulorrhexis. Also it has been used in two recent studies on equine cornea: an *in vitro* model for corneal scarring treatment with mitomycin C and a novel model method of gene delivery [78, 79].

Anterior chamber and iris examination

The intraocular portion of the ocular examination is conducted next. See Chapter 8 regarding the anatomy and diseases of the anterior chamber and uvea of the horse's eye. With a thin beam (slit) or small circular beam of light from the light source directed at a 45-degree angle to the eye, the anterior chamber depth and clarity are inspected. In a healthy horse, this will not result in any internal reflection of light from the aqueous, and the anterior chamber should appear clear (Figure 1.35). If solids (e.g., protein, cells) are present in the aqueous, there will be a reflection of light from these particles (i.e., the Tyndall effect) [12]. This turbidity results in visualization of the beam of light traversing the anterior chamber and is referred to as **aqueous flare**. Aqueous flare (and other ocular lesions such as corneal edema, corneal pigment, and conjunctival redness) can be graded on a subjective scale from 1+ to 4+, with 4+ being the greatest degree of severity.

Tonometry

Measurement of intraocular pressure (IOP) in the horse has been revolutionized by the development of handheld portable digital tonometers. Direct tonometry via a manometer is the most accurate but invasive method for recording the IOP and is not practical for clinical use. Indirect tonometry, the measurement of corneal tension, is the technique used to determine IOP in clinical veterinary ophthalmology [17]. Digital, indentation, and applanation tonometry have all been described in the horse [12]. Digital tonometry, the estimation of IOP by digital palpation, can be considered just approximate but not accurate. Indentation tonometry, commonly performed with a Schiottz tonometer, requires general anesthesia (a lateral position) in the horse and is impractical. However, normal values have been reported for the Schiottz tonometer in the horse and are 14–22 mm Hg [17]. Applanation tonometry measures the amount of flattening (area of contact) of the cornea when a weight touches it [12, 17]. The force it takes to flatten this portion of the cornea is an estimate of the IOP (pressure = force/area). Rebound tonometry (TonoVet tonometer (ICare Finland Oy, Helsinki)) is another method to measure IOP in horses. This uses a disposable probe that is electromagnetically propelled to contact the cornea, then rebound to the instrument, which then uses these rebound characteristics to estimate IOP [80]. Accurate measurement of IOP in the standing horse requires use of applanation or rebound tonometry (Figure 1.36) [8, 12]. In one study involving normal horses, the TonoVet rebound tonometer correlated well to manometry IOP measurements, and IOPs obtained with the TonoVet rebound tonometer (Figure 1.37) were higher than with the Tono-Pen applanation tonometer (Figure 1.38) [80].

Tonometry is part of routine ocular examination and it is particularly indicated in horses with focal or diffuse corneal edema, a red or painful eye, orbital trauma, ocular blunt trauma, exophthalmos or hydrophthalmos, a history of glaucoma in the

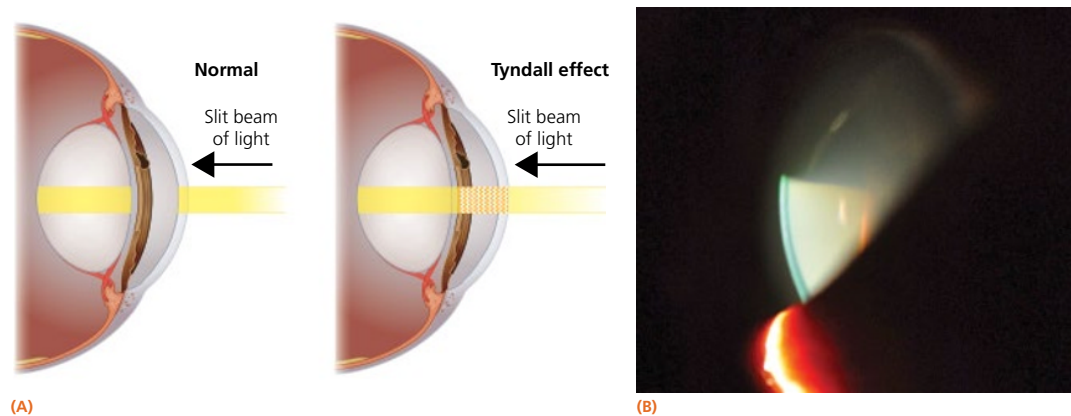


Figure 1.35 (A) With a thin beam (slit) or small circular beam of light from the light source directed at a 45-degree angle to the eye, the anterior chamber depth and clarity are inspected. In a healthy horse, this will not result in any internal reflection of light from the aqueous, and the anterior chamber should appear clear. If solids (e.g., protein, cells) are present in the aqueous, there will be reflection of light from these particles (i.e., the Tyndall effect). (Source: Illustrations by Samantha J Elmhurst BA Hons/LivingArt.) (B) This turbidity results in visualization of the beam of light traversing the anterior chamber and is referred to as aqueous flare.

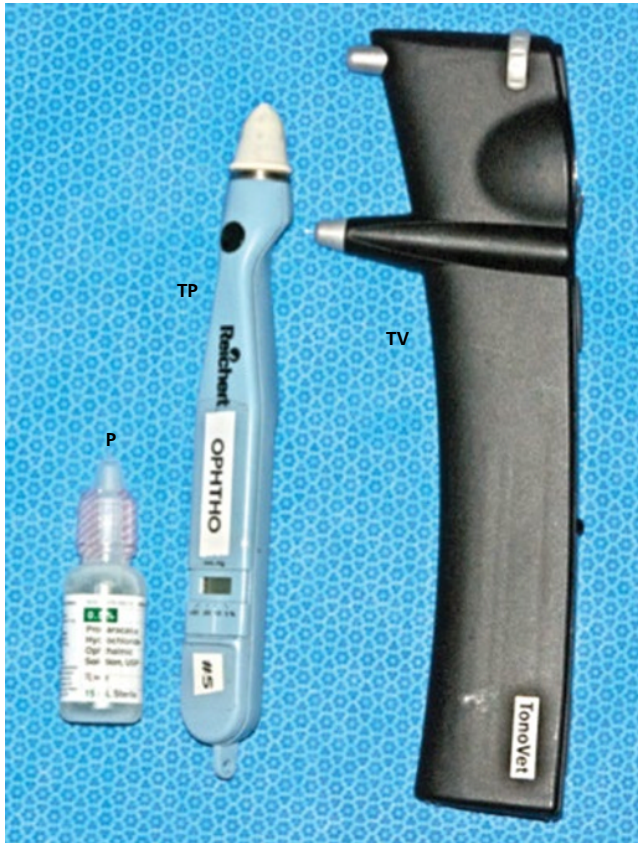

Figure 1.36 Materials needed to perform tonometry in the horse. Accurate measurement of IOP in the standing horse requires tonometry, either using a Tono-Pen digital tonometer (TP) or a TonoVet rebound tonometer (TV), or similar instrument. The Tono-Pen tonometer requires use of a topical anesthetic, such as 0.5% proparacaine HCl (P), while the TonoVet does not.



Figure 1.37 Tonometry in the horse using a TonoVet tonometer.

opposite eye, or a lens subluxation/luxation; it is also indicated for follow-up examinations of animals with medically controlled glaucoma [8, 12]. Three separate readings with less than 5% standard error are averaged to obtain the IOP in millimeters of mercury [12, 17]. If significant corneal disease is present, the

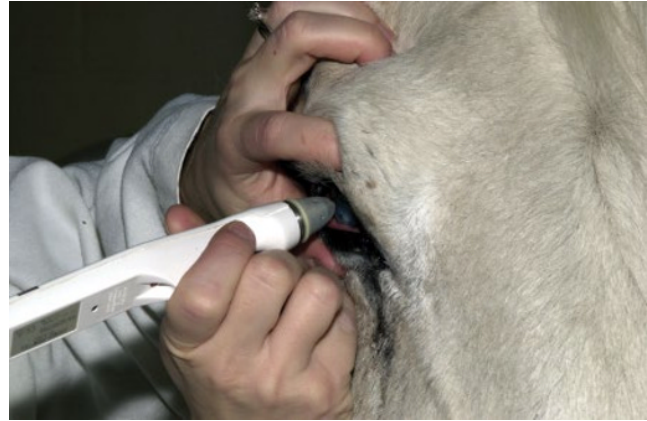

Figure 1.38 Tonometry in the horse using a Tono-Pen tonometer.

most normal part of the cornea should be used to take readings [17]. A fibrotic or edematous cornea may result in a falsely elevated IOP [17]. See Chapter 10 for more information on the diagnosis and treatment of glaucoma.

Horses that require sedation for ocular examination may show dramatic decreases in IOP, as illustrated by one study in which xylazine decreased IOP by 23% [81]. In another report, the IOP range was 20.5–39.8 mm Hg and showed that both acepromazine and xylazine decreased IOP [82]. A combination of xylazine and ketamine had no effect [83, 84]. The effect of IV administration of romifidine on IOP in normal horses has been recently described by two publications. In the first report, a consistent decrease of IOP after romifidine IV administration (75 µg/kg) was noted, with the largest change from baseline values (16.7%) at 15 minutes after injection [85]. The second report describes a highly significant IOP decrease 45 minutes after IV injection of romifidine (40 µg/kg) in right eyes (58.5% decrease) and left eyes (55.2% decrease) from the baseline values. In this second report, IOP values returned to normal 120 minutes after the IV injection [86]. It has been suggested that horses without an auriculopalpebral block will have an elevated IOP due to eyelid tension [17, 84] but this has not been supported in two other studies in normal horses [81, 87]. However, horses with ocular disease such as glaucoma may be blepharospastic; therefore auriculopalpebral blocks are recommended prior to tonometry. IOP in normal horses without an auriculopalpebral nerve block has been reported as ranging from 24.5 ± 4.0 mm Hg to 28.6 ± 4.8 mm Hg, while baseline IOP values in horses with auriculopalpebral nerve block has been reported as ranging from 24.25 ± 3.5 mm Hg to 26.35 ± 5.57 mm Hg [80, 85, 86, 88]. In one study of normal horses in which horses were tranquilized with detomidine and given auriculopalpebral nerve blocks, 87% of horses with their head positioned lower than their hearts had elevated IOP [89]. In another study, circadian rhythm was shown to have an influence on horses' IOP [90]. In this study, IOP was found to be low during the dark phase and high during the light phase, with a peak at the end of the light phase [90]. Evaluating the results of these studies together, it is